

Subbrachial approach to humeral shaft fractures: new surgical technique and retrospective case series study

Vladimir Boschi, MD, PhD*
 Zenon Pogorelic, MD, PhD†
 Gordan Gulan, MD, PhD‡
 Katarina Vilovic, MD, PhD§
 Hrvoje Stalekar, MD, PhD¶
 Kanito Bilan, MD*
 Leo Grandic, MD, PhD*

From the *Department of Surgery, University Hospital Split and Split University School of Medicine, the †Department of Pediatric Surgery, University Hospital Split and Split University School of Medicine, Split, the ‡Orthopedic Clinic Lovran, Lovran, the §Department of Anatomy and Pathology, University Hospital Split and Split University School of Medicine, and the ¶Department of Surgery, University Hospital Rijeka and Rijeka University School of Medicine, Rijeka, Croatia

Accepted for publication
 Sept. 6, 2011

Correspondence to:
 Z. Pogorelic
 Department of Pediatric Surgery
 University Hospital Split
 Spinciceva 1
 21 000 Split
 Croatia
 zenon@vip.hr

DOI: 10.1503/cjs.011911

Background: There are few surgical approaches for treating humeral shaft fractures. Here we present our results using a subbrachial approach.

Methods: We conducted a retrospective case series involving patients who had surgery for a humeral shaft fracture between January 1994 and January 2008. We divided patients into 4 groups based on the surgical approach (anterior, anterolateral, posterior, subbrachial). In all patients, an AO 4.5 mm dynamic compression plate was used.

Results: During our study period, 280 patients aged 30–36 years underwent surgery for a humeral shaft fracture. The average duration of surgery was shortest using the subbrachial approach (40 min). The average loss of muscle strength was 40% for the anterolateral, 48% for the posterior, 42% for the anterior and 20% for the subbrachial approaches. The average loss of tension in the brachialis muscle after 4 months was 61% for the anterolateral, 48% for the anterior and 11% for the subbrachial approaches. Sixteen patients in the anterolateral and anterior groups and 6 patients in the posterior group experienced intraoperative lesions of the radial nerve. No postoperative complications were observed in the subbrachial group.

Conclusion: The subbrachial approach is practical and effective. The average duration of the surgery is shortened by half, loss of the muscle strength is minimal, and patients can resume everyday activities within 4 months. No patients in the subbrachial group experienced injuries to the radial or musculocutaneous nerves.

Contexte : Il existe peu d'approches chirurgicales pour corriger la fracture de la diaphyse humérale. Nous présentons ici les résultats que nous avons obtenus avec une approche sous-brachiale.

Méthodes : Nous avons réalisé une série de cas rétrospective regroupant des patients ayant subi une chirurgie pour réparation de fracture de la diaphyse humérale entre janvier 1994 et janvier 2008. Nous avons divisé les patients en 4 groupes selon l'approche chirurgicale employée (antérieure, antérolatérale, postérieure et sous-brachiale). Nous avons utilisé une plaque de compression dynamique AO de 4,5 mm.

Résultats : Pendant la période de l'étude, 280 patients de 30 à 36 ans ont subi une chirurgie pour fracture de la diaphyse humérale. La durée moyenne de la chirurgie a été la plus courte avec l'approche sous-brachiale (40 min). La perte moyenne de force musculaire a été de 40 %, 48 %, 42 % et 20 % avec les approches antérolatérale, postérieure, antérieure et sous-brachiale, respectivement. La perte moyenne de tension dans le muscle brachial après 4 mois était respectivement de 61 %, 48 %, et 11 % avec les approches antérolatérale, antérieure et sous-brachiale. Seize patients des groupes soumis aux approches antérolatérale et antérieure et 6 patients du groupe soumis à l'approche postérieure ont subi des lésions peropératoires du nerf radial. Aucune complication postopératoire n'a été observée dans le groupe soumis à l'approche sous-brachiale.

Conclusion : L'approche sous-brachiale est pratique et efficace. La durée moyenne de l'intervention est abrégée de moitié, la perte de force musculaire est minimale et les patients peuvent reprendre leurs activités courantes en l'espace de 4 mois. Aucun des patients du groupe traité par l'approche sous-brachiale n'a subi de lésions des nerfs radial ou musculocutané.

Humeral fractures account for about 3% of all fractures. About 30% of these injuries need to be treated surgically.¹ Fractures of the humeral shaft are a result of direct force during impact, traffic accidents or crush injuries. Indirect forces, such as a fall on the elbow or extended arm or

strong muscular contractions, can result in a fractured humerus. The most frequent site of the fracture is between the middle and the distal third of the humerus.¹⁻³

Because of the close anatomic relationship between the radial nerve and humerus, nerve injuries are frequent, especially with spiral fractures. The frequency of radial nerve injury caused by fractures is 6%–15%.⁴ Brachial artery injuries as a result of the humeral fracture itself are very rare. They are usually reported in cases of proximal and supracondylar humeral fractures.^{5,6} Uncomplicated humeral shaft fractures are usually treated conservatively. The usual operative methods used are the dynamic compression plate (DCP) and intramedullary nail.^{3,7,8} Plate fixation results in high union rates, but requires extensive dissection and stripping of soft tissues from the bone, which is associated with a greater risk of radial nerve damage.⁷⁻⁹ The neurovascular and muscular anatomy of the humerus precludes the use of a fully extensile approach that is truly safe.

Currently, there are a few surgical approaches for treating humeral fractures: anterior, anterolateral, posterior and lateral.¹⁰⁻¹² The posterior and anterolateral approaches are the most frequently used because they allow access to a larger segment of the humerus. The lateral approach is used for the distal quarter of the humerus.^{7,8,10-13} Surgical treatment carries specific risks related to the close anatomic relationships among the bone, nerves and blood vessels. Iatrogenic injury of the radial nerve occurs in 10%–25% of patients as a result of contusion, stretch or direct damage.^{4,14} The infection rate is about 6%.^{3,15} In conservative treatment, nonunion occurs in about 2% of patients;⁹

in operative treatment using DCP, nonunion occurs in 8% of patients, and with intramedullary osteosynthesis nonunion occurs in 10%–33%.^{16,17}

We present our results using a new subbrachial surgical approach to the mid third of the humeral shaft fracture.

METHODS

Patients

We reviewed the case records of patients who underwent surgery for a fracture of the humeral diaphysis in the department of traumatology, University Hospital Split, Croatia, between January 1994 and January 2008. Our inclusion criteria were male sex, age 30–36 years and mid-third shaft fracture. We required that the injury mechanism of included patients was a direct blow to the upper arm as a result of sport activities, motor vehicle or bicycle crashes, or a fall. Patients with pathological fractures, refractures, old neglected fractures, grade III open fractures of the humerus or neurovascular injury were excluded from our study. After clinical examination, all patients underwent routine radiography (anteroposterior and lateral; Fig. 1A). We classified fractures according to the AO classification.

We divided patients into 4 groups based on the surgical approach (anterolateral, anterior, posterior, subbrachial). Four experienced surgeons were involved in this study, and they each performed an approximately equal number of operations. The approach used was the surgeon's choice.

In all patients, an AO 4.5 mm dynamic compression

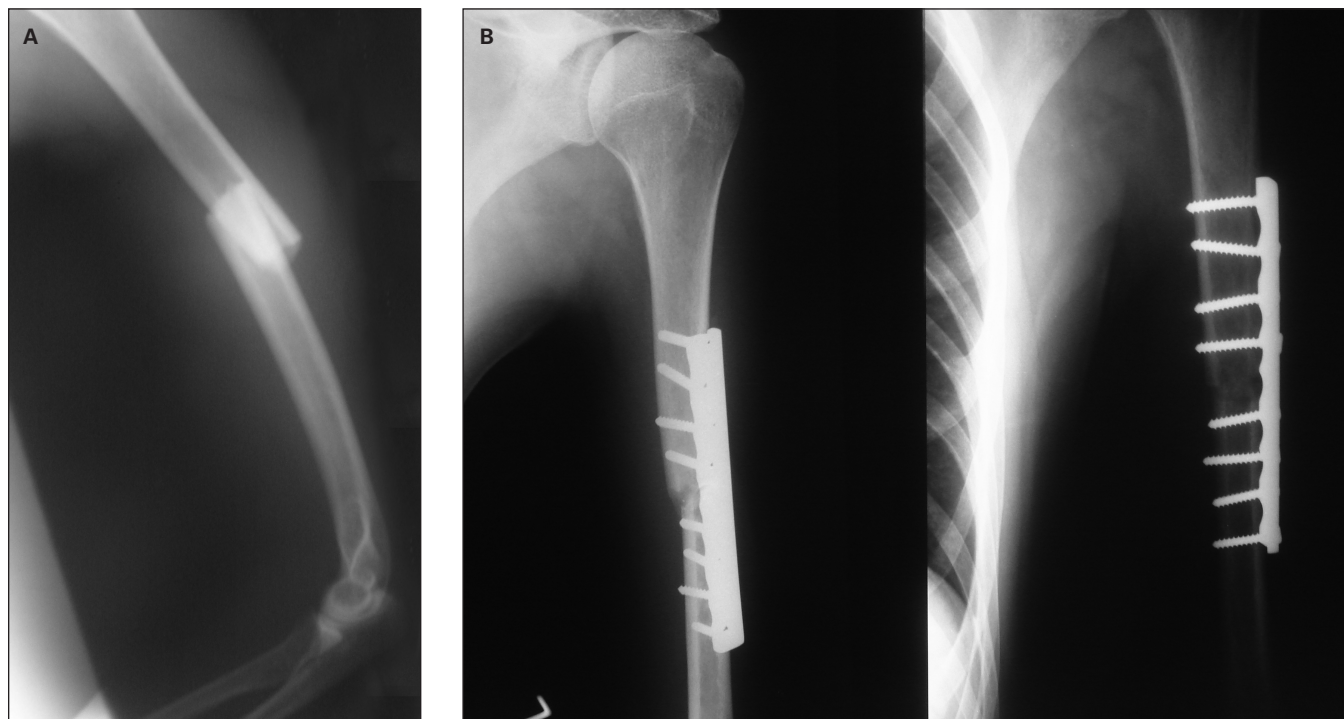


Fig. 1. (A) Pre- and (B) postoperative radiographs of a humeral shaft fracture.

plate (AO-DCP; Synthes) with 6–8 screws was used (Fig. 1B). After surgery, we used 12 Ch Redon drains (Braun Melsungen AG) for a period of 48 hours. Prophylactic antibiotic therapy was not used. The stitches were removed 10–12 days after surgery in all patients. Rehabilitation started with active hand, wrist and elbow mobilization with gentle pendulum exercises of the shoulder for 2 weeks, followed by active, assisted exercises for 4 weeks. Loss of muscle strength, muscular capacities and success of rehabilitation was measured using the Cybex II dynamometer.¹⁸

To check the brachialis muscle's potential, electromyoneurography was performed by placing the electrode directly into the muscle. Both arms were checked in each patient with maximal elbow flexion using a 2 kg weight. The difference between the potentials and the amplitude on the operated and nonoperated sides were recorded as percentages. The test occurred in the fourth and the eighth months after the operation, when such activities were possible.

The patients were followed up at week 6 and at months 3, 4, 6, 8, 12 and 24. Clinical and radiological assessments occurred at each visit. We defined union as fracture healing within 6 months after treatment. We considered healing between 6 months and 1 year to be a delayed union. Frac-

tures not healed within 1 year and those requiring reosteosynthesis were classified as nonunions.

Surgery

The patient was in the supine position with the shoulder in a mild abduction and the arm positioned on the table (Fig. 2A). With the elbow flexed, the biceps brachii was moved in the medial–lateral direction. This is an important manoeuvre, because the limits of the biceps and the position of an incision can be defined. The skin incision starts from the lateral site 1 cm below the edge of the biceps brachii muscle and follows its border (Fig. 2B and 3A), avoiding the cephalic vein. The radial nerve runs in the spiral groove posteriorly and then laterally around the humerus. The nerve can be located either by the lateral edge of the brachialis muscle or inside the lateral part of the muscle (Fig. 4A). Using this approach, the whole brachialis muscle is spared owing to a kind of “protecting zone” between the operative field and the radial nerve. The separation of the biceps and the brachialis muscle begins proximally. With this approach there is no need to expose the radial and the musculocutaneous nerves

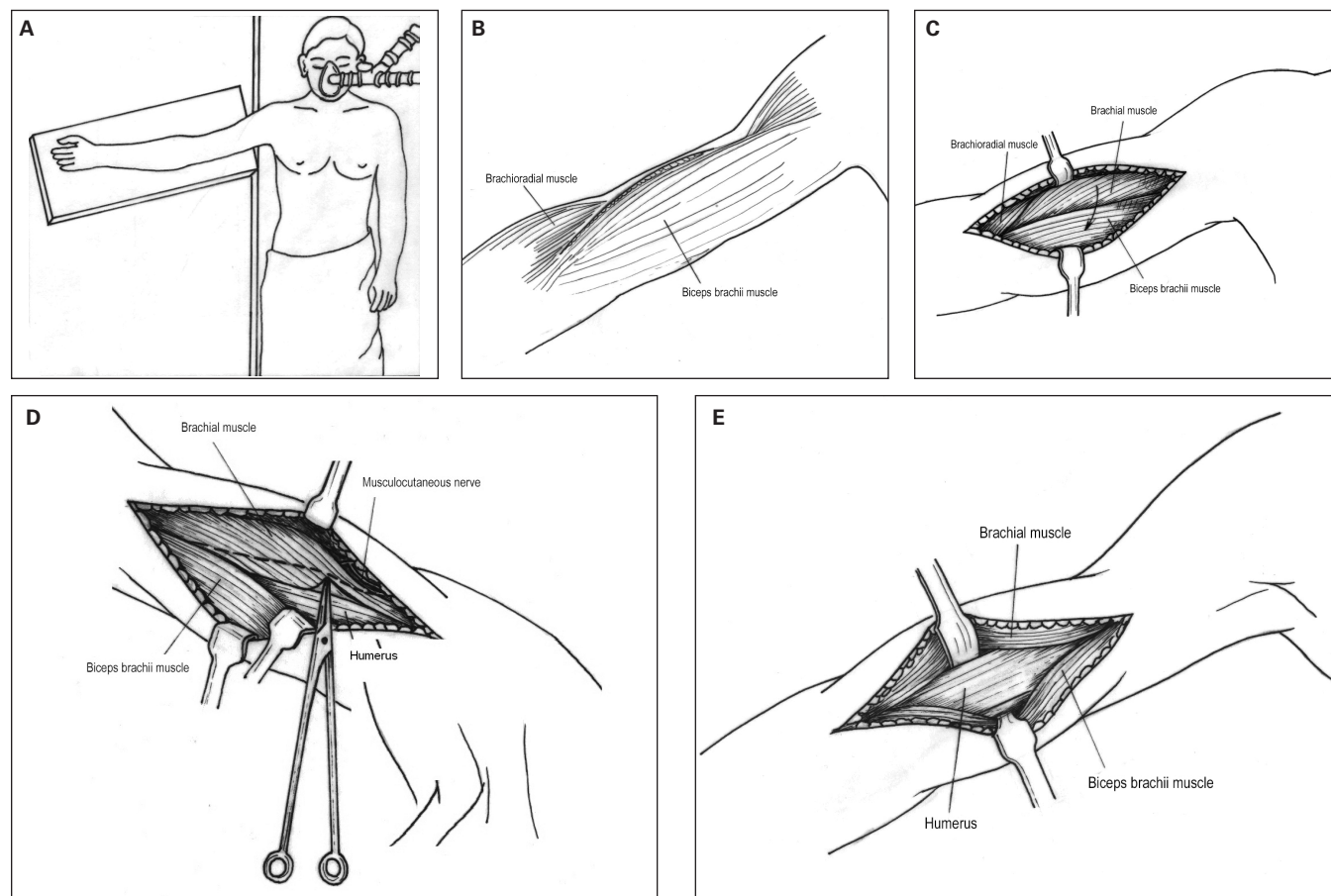


Fig. 2. Schematic view of the subbrachial approach showing (A) position of the arm, (B) place of the skin incision, (C) separation of the edges of the brachialis muscle and biceps brachii muscle, (D) separation of the brachialis muscle to the humerus and (E) exposure of the humerus by subperiosteal hook placing.

because they are outside of the operative field (Fig. 4B). By moving the skin and fascia aside, the biceps brachii and the brachialis muscles connected by the intermuscular connective tissue are exposed. The edges of both muscles that are parallel and sporadically separated by a loose connective tissue have to be defined (Fig. 2C and 3B).

Unlike the anterolateral and the anterior approaches in which the brachialis muscle is cut through, with the subbrachial approach we move medially, following the edge of the brachialis muscle and isolating it from the biceps brachii muscle's lateral edge toward the humerus using blunt dissection. The isolation begins proximally to avoid the musculocutaneous nerve, which is not in the intermuscular area at that point. This way, we approach the humerus from the place where the medial part of the brachialis muscle is loosely attached to the bone. From there, the muscle isolation procedure can be performed distally (for the middle and the distal third of the humeral diaphysis). Initially, the muscle is isolated by a blunt instrument and then by a blunt finger dissection (Fig. 2D and

3C). The brachialis muscle can easily be taken off and moved laterally and back using subperiosteal hooks. In this way, the anterior lateral and medial part of the humerus is exposed (Fig. 2E and 3D).

Statistical analysis

We performed our statistical analyses using Statistica for Windows Release version 12.0 (StatSoft) and Microsoft Excel for Windows version 11.0. The χ^2 , Student *t*, Mann-Whitney *U* and Kolmogorov-Smirnov tests were used.

RESULTS

Patients

During the study period 280 men (mean age 33.5 [range 30–36] yr) underwent surgery to treat a fracture of the humeral diaphysis. There were 70 patients in each of the 4 groups (anterior, anterolateral, posterior, subbrachial).

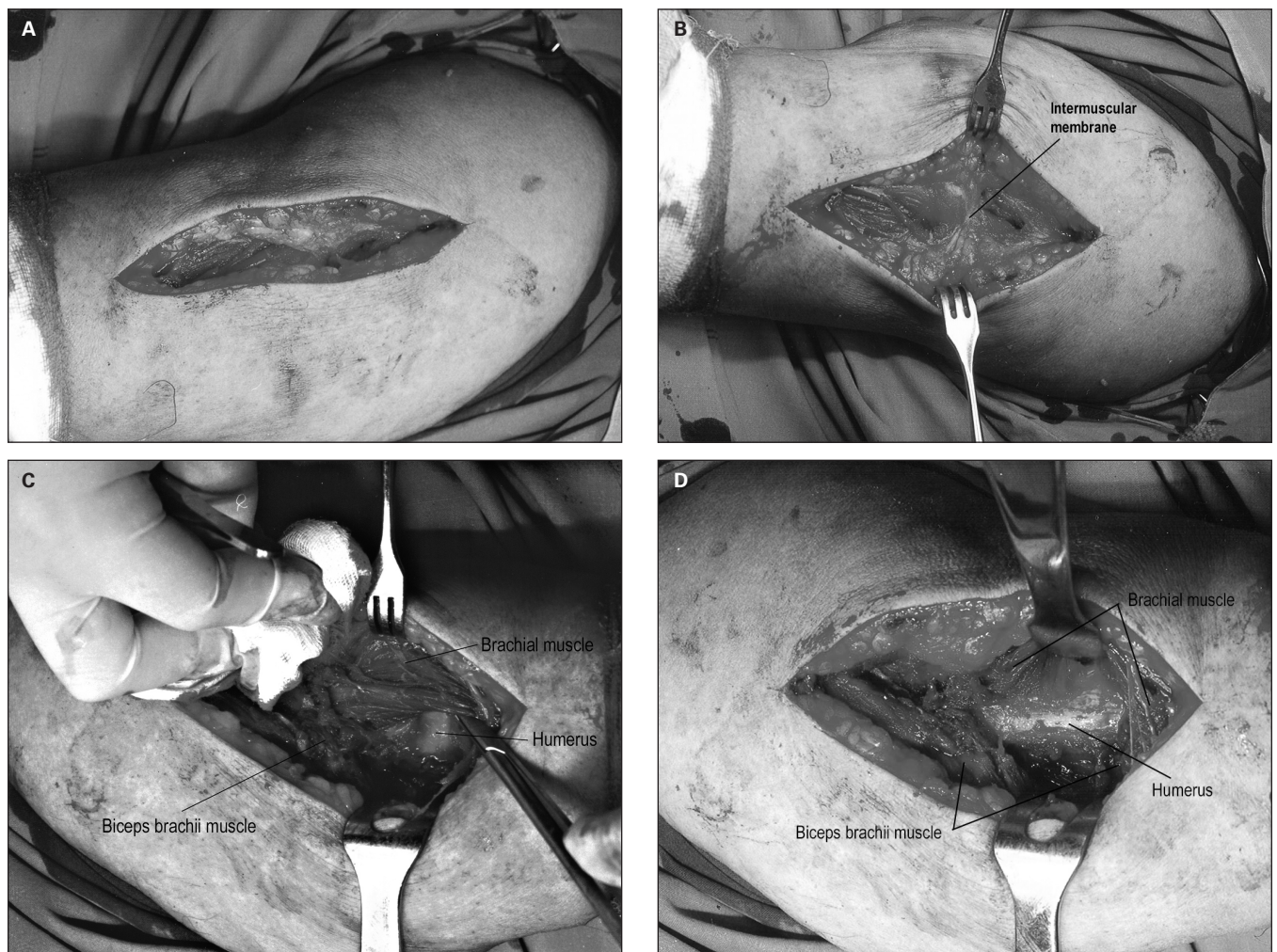


Fig. 3. Intraoperative view of the subbrachial approach showing (A) incision of the skin, (B) surgical approach to intermuscular membrane, (C) separation of the edges of the brachialis and biceps brachii muscles and (D) exposure of the humerus.

The right humerus was involved in 179 patients and the left in 101. Using AO classification, we categorized fractures as follows: A1 in 74 patients, A2 in 56, A3 in 80, B1 in 41 and B2 in 29. The mean duration of follow-up was 8.4 years.

Fracture union

Union was achieved in 98.2% of patients and delayed union in 1.8%; nonunion was not observed. On average, it took 14.5 weeks to achieve union; it took an average of 15.1 weeks for patients in the anterolateral, 14.7 in the anterior, 14.1 in the posterior and 14.6 in the subbrachial groups. There was no significant difference between the union rate and the incidence of nonunion among the groups.

Duration of surgery

The duration of surgery was measured in minutes from the moment of the skin incision to the moment of wound closure. The average duration of surgery was 70 minutes for the anterolateral, 60 for the anterior, 75 for the posterior and 40 for the subbrachial approaches. The duration of surgery using the subbrachial approach was significantly shorter than that for the other approaches ($p < 0.001$).

Muscle strength

We tested flexor muscle strength for each patient. We measured loss of muscle strength in the arm that received surgery in comparison to the healthy arm. The average loss of muscle strength measured 4 months after the opera-

tion using a Cybex II instrument was 40% in the anterolateral, 48% in the posterior, 42% in the anterior and 20% in the subbrachial groups.

We performed the same test 8 months after the surgery. The average loss of muscle strength was 11% in the anterolateral, 12% in the posterior, 9% in the anterior and 3% in the subbrachial groups. The loss of muscle strength was significantly less in the subbrachial than in the other groups ($p < 0.001$).

Electromyoneurography

We used electromyoneurography, with effort in the healthy arm and the arm that received surgery, to determine the difference in loss of tension at the willing flexion. We compared the values obtained for both arms 4 months after surgery for each patient. The average loss of tension was 61% in the anterolateral and 49% in the anterior groups, but 11% for the subbrachial group.

We repeated the test 8 months after surgery. The average loss of tension in the brachialis muscle was 41% in the anterolateral and 31% in the anterior groups, but 5% for the subbrachial group. We did not perform this test in the posterior group because there was no brachialis muscle damage. The average loss of tension was significantly less in the subbrachial group ($p < 0.001$).

Postoperative complications

Of the 140 patients in the anterolateral and anterior groups, 1 (< 1%) patient experienced a secondary infection

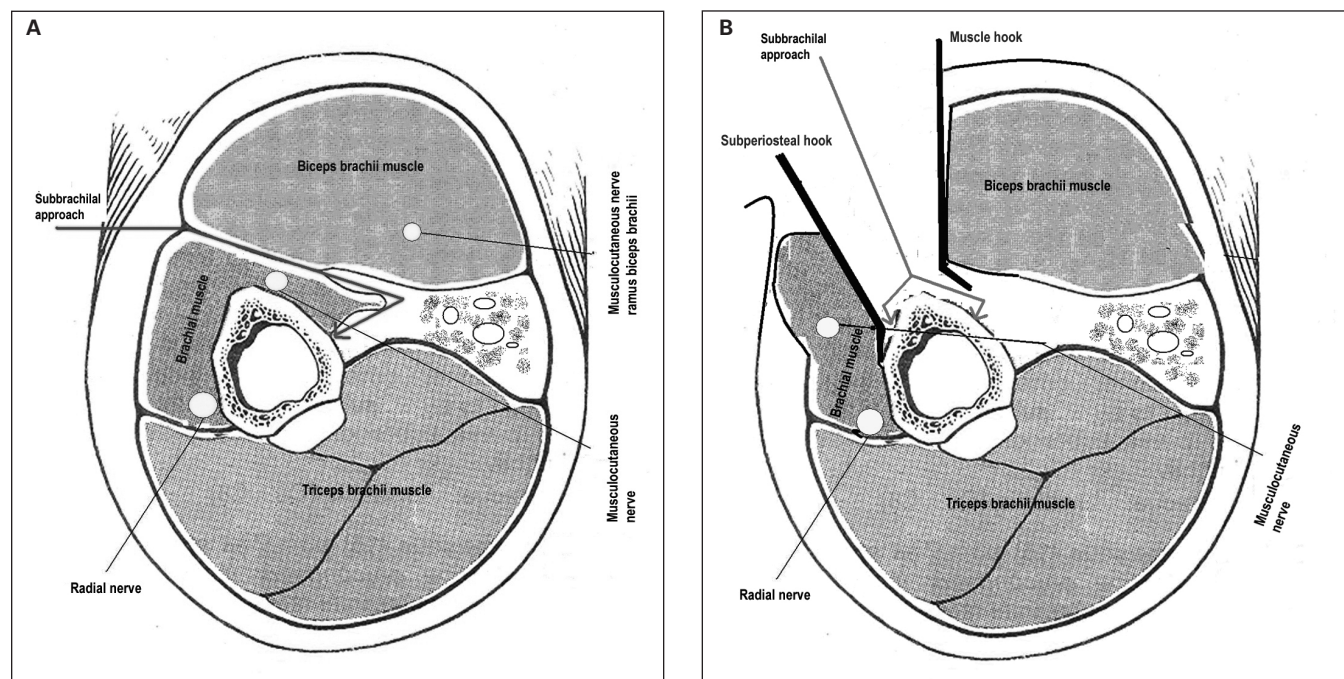


Fig. 4. Sagittal section of the upper arm with (A) a view of the direction of the subbrachial approach and (B) a view of the humerus after hook placing. The radial and musculocutaneous nerves are protected by the brachialis muscle.

and 16 (11%) experienced intraoperative injury of the radial nerve (strain or contusion). There were 6 (9%) patients in the posterior group who experienced radial nerve injury, and no patients in the subbrachial group experienced radial nerve injury. None of the patients had neurologic deficit before surgery.

The difference in the lesion of the radial nerve among the compared groups was significant ($p < 0.001$). The radial nerve lesions were verified by the clinical examination electromyoneurography.

DISCUSSION

The incidence of humeral shaft fractures has increased in the last 30 years in relation to the incidence of other tubular bone fractures. Despite safer motor vehicles and the development of airbags,² the arms remain relatively unprotected in motor vehicle collisions. In addition, changes in the everyday activities of the population, robotization and other technological changes in industry cause arms to be more exposed to machines.^{2,3,10}

Any discussion about surgical treatment of humeral shaft fractures must first consider the excellent results that can be achieved with nonoperative care of this type of fracture, which has been associated with union rates of more than 90% and with full functional recovery.^{3,7,8,11} However, certain fracture types and associated injuries require operative management. Apart from intramedullar osteosynthesis, anterolateral and anterior approaches have been used to treat humeral fractures.¹⁰⁻¹² In the anterolateral and anterior approaches, the brachialis muscle is cut to reach the diaphysis of the humerus. Both these approaches can cause iatrogenic injuries of the radial nerve, and the anterior approach can cause injuries of the musculocutaneous nerve. The anterolateral approach is more often used to expose the distal third of the humerus, and the brachialis muscle is cut a bit more laterally.^{4,10-12,14} Except for the very end of the distal part of the diaphysis and the proximal third of the diaphysis, both methods involve the same principles of approaching the diaphysis of the humerus. With these approaches, the anterolateral part of the humerus can be exposed; therefore, some authors refer to both methods as the anterolateral approach.¹⁰⁻¹²

The musculocutaneous nerve passes between the biceps and the brachialis muscle. After sending a motor branch to the biceps, the musculocutaneous nerve is located inside the brachialis muscle. After the motor branch has been separated, the musculocutaneous nerve goes out of the brachialis muscle and enters the intermuscular sulcus.¹⁹⁻²² With the anterior approach, the musculocutaneous nerve can be damaged during operative manipulation. Considering that the nerve is placed near or within the operative field, the best way to avoid damage is to move its covering structures away to expose the whole nerve in the operative field. Some authors do not attach much importance to the exposure of

the musculocutaneous nerve because it is far enough from the location of the incision in the brachialis muscle that they believe it cannot be damaged.^{23,24} Other authors consider it necessary to expose the musculocutaneous nerve because its position varies and thus can be placed in the area where we cut the brachialis muscle.^{4,10,25,26} With the subbrachial approach, there is no need to expose the musculocutaneous nerve, because it stays inside the brachialis muscle, protected by the muscle tissue, outside of the operative field. When isolating the muscle distally the musculocutaneous nerve stays by the brachialis muscle.²⁰⁻²²

There are conflicting opinions about treating the radial nerve during the surgery; however, most authors agree that if the radial nerve is not exposed, there is a risk of iatrogenic injury.^{4,10,14,27,28} The occurrence of an intraoperative lesion of the radial nerve is also emphasized with the anterolateral and anterior approaches; injury rates of 5%–20% have been recorded.^{4,10,14,27} Of the patients in our series who underwent the anterolateral and the anterior approaches, 11% experienced an intraoperative lesion of the radial nerve due to contusion or strain. These results correspond with those reported in the literature.^{4,10,11,14}

With the subbrachial approach, the nerves are protected by the brachialis muscle, minimizing the risk of injuring either the radial or musculocutaneous nerve.

In 81% of patients, there is dual innervation of the brachialis muscle.^{20,21} It comes from the radial and the musculocutaneous nerves, with some variations in the involvement of those nerves. The innervation from the musculocutaneous nerve is 70%–90% and that from the radial nerve is 10%–30%.^{19,22} Because of dual innervation, some authors prefer the technique of cutting the brachialis muscle to reach the humerus. By cutting the brachialis muscle, 2 segments with undamaged innervations are exposed.^{9,24} These authors also report that the brachialis muscle is bluntly cut between the filaments and that it does not cause major necrosis of the muscle.^{9,24,25} Other authors claim that it is not possible to halve the muscle by moving the filaments aside without subsequent major muscle necrosis and that it is not possible to cut the brachialis muscle in such a way that the innervations in the 2 segments are never damaged.^{10,27,29,30}

Mills and colleagues³¹ were the first to emphasize the importance of preserving the brachialis muscle on the assumption that it would lead to better outcomes. To avoid muscle damage, the surgical section must be placed laterally between the triceps brachii muscle and the brachialis muscle without cutting it, exposing the radial nerve. Unfortunately, this theory about the preservation of the brachialis muscle was not corroborated with scientific evidence.³¹ There are similar modifications of the lateral approach, where authors emphasize the need to preserve the brachialis muscle.^{10,24,32,33}

We showed that cutting the filaments of the brachialis muscle leads to functional muscle damage with a consecutive decrease of raw strength, which requires longer

convalescence. Electromyography revealed significant damage of the brachialis muscle in patients whose muscles were cut.

The results of our muscle strength test, measured by the Cybex instrument, show that patients who underwent the standard (anterior and anterolateral) approaches, which involved cutting the brachialis muscle, experienced a significant loss of muscle strength. Our results correspond with those of other studies, in which the intact muscle was tested in relation to the muscle that had been damaged by cutting or blunt dissection.¹⁸

With the subbrachial approach, electromyoneurography results revealed that damage was minimal, rehabilitation was faster and the outcome was closer to the physiologic norm. Eight months postoperatively, there was persistent weakness of the brachialis muscle, demonstrated by electromyoneurography, in the patients who underwent the standard approaches. The success of their rehabilitation was probably compensated by the hypertrophy of the other forearm flexors.

The duration of surgery is a risk factor for infection. Longer operative manipulation in terms of cutting or compression leads to tissue damage and necrosis. Longer exposure of the osteosynthetic material accelerates the adherence of metalotropic micro-organisms.^{15,34} The occurrence of an infection after the anterolateral and anterior approach and internal fixation has been reported to be up to 6%.¹¹ We noted 1 case of an infection with the anterolateral and anterior approaches and no cases with the subbrachial approach. Prolonging the duration of the surgery enlarges the concentration of metalotropic micro-organisms.³⁴ Every 60 minutes of surgery increases the incidence of infection by 2%.³⁴ Besides the duration of surgery, a very important factor is surgical technique with minimal soft tissue damage and hematoma forming. The subbrachial approach minimizes muscle devitalization, and there is no associated bleeding or hematoma. The average duration of surgery with the anterolateral and anterior approaches is 65–70 minutes,^{10,11} whereas surgery with subbrachial approach is shortened by 30 minutes, which may decrease the risk of infection.

CONCLUSION

The subbrachial approach is practical and effective for exposing the anterior lateral and medial mid-third of the humerus. The average duration of surgery is shortened by half compared with anterior and anterolateral approaches. The risk of injury to the radial and musculocutaneous nerves is also decreased. Rehabilitation time is shortened with more complete muscle recovery.

Competing interests: None declared.

Contributors: V. Boschi, Z. Pogorelic, G. Gulan, K. Bilan and L. Grandic designed the study. Z. Pogorelic acquired the data. V. Boschi, Z. Pogorelic, K. Vilovic, H. Stalekar and K. Bilan analyzed it. V. Boschi,

Z. Pogorelic, K. Vilovic and K. Bilan wrote the article, which V. Boschi, G. Gulan, H. Stalekar and L. Grandic reviewed. All authors approved publication.

References

1. Broadbent MR, Quaba O, Hadjucka C, et al. The epidemiology of multifocal upper limb fractures. *Scand J Surg* 2003;92:220-23.
2. Stuby FM, Höntzsch D. Humerus shaft fractures. *Z Orthop Unfall* 2009;147:375-86.
3. Smejkal K, Dedek T, Lochman P, et al. Operation treatment of the humeral shaft fractures. *Rozhl Chir* 2008;87:580-4.
4. Bishop J, Ring D. Management of radial nerve palsy associated with humeral shaft fracture: a decision analysis model. *J Hand Surg Am* 2009;34:991-6.
5. Hasan SA, Cordell CL, Rauls RB, et al. Brachial artery injury with a proximal humerus fracture in a 10-year-old girl. *Am J Orthop* 2009;38:462-6.
6. Noaman HH. Microsurgical reconstruction of brachial artery injuries in displaced supracondylar fracture humerus in children. *Microsurgery* 2006;26:498-505.
7. Spitzer AB, Davidovitch RI, Egol KA. Use of a "hybrid" locking plate for complex metaphyseal fractures and nonunions about the humerus. *Injury* 2009;40:240-4.
8. Putti AB, Uppin RB, Putti BB. Locked intramedullary nailing versus dynamic compression plating for humeral shaft fractures. *J Orthop Surg (Hong Kong)* 2009;17:139-41.
9. Rüedi T, Moshfegh A, Pfeiffer KM, et al. Fresh fractures of the shaft of the humerus. Conservative or operative treatment? *Reconstr Surg Traumatol* 1974;14:65-74.
10. Zlotolow DA, Catalano LW III, Barron OA, et al. Surgical exposures of the humerus. *J Am Acad Orthop Surg* 2006;14:754-65.
11. Hannouche D, Ballis R, Raouf A, et al. A lateral approach to the distal humerus following identification of the cutaneous branches of the radial nerve. *J Bone Joint Surg Br* 2009;91:552-6.
12. Bamrungthin N. Comparison of posterior and lateral surgical approach in management of type III supracondylar fractures of the humerus among the children. *J Med Assoc Thai* 2008;91:502-6.
13. O'Toole RV, Andersen RC, Vesnovsky O, et al. Are locking screws advantageous with plate fixation of humeral shaft fractures? A biomechanical analysis of synthetic and cadaveric bone. *J Orthop Trauma* 2008;22:709-15.
14. Elton SG, Rizzo M. Management of radial nerve injury associated with humeral shaft fractures: an evidence-based approach. *J Reconstr Microsurg* 2008;24:569-73.
15. Neumaier M, Scherer MA. C-reactive protein levels for early detection of postoperative infection after fracture surgery in 787 patients. *Acta Orthop* 2008;79:428-32.
16. Nadkarni B, Srivastav S, Mittal V, et al. Use of locking compression plates for long bone nonunions without removing existing

- intramedullary nail: review of literature and our experience. *J Trauma* 2008;65:482-6.
17. Wu CC, Shih CH. Treatment for nonunion of the shaft of the humerus: comparison of plates and Seidel interlocking nails. *Can J Surg* 1992;35:661-5.
 18. Cahalan TD, Johnson ME, Chao EY. Shoulder strength analysis using the Cybex II isokinetic dynamometer. *Clin Orthop Relat Res* 1991;271:249-57.
 19. Mahakkanukrauh P, Somsarp V. Dual innervation of the brachialis muscle. *Clin Anat* 2002;15:206-9.
 20. Yan J, Aizawa Y, Honma S, et al. Re-evaluation of the human brachialis muscle by fiber analysis of supply nerves. *Kaibogaku Zasshi* 1998;73:247-58.
 21. Frazer EA, Hobson M, McDonald SW. The distribution of the radial and musculocutaneous nerves in the brachialis muscle. *Clin Anat* 2007;20:785-9.
 22. Chiarapattanakom P, Leechavengvongs S, Witoonchart K, et al. Anatomy and internal topography of the musculocutaneous nerve: the nerves to the biceps and brachialis muscle. *J Hand Surg Am* 1998;23:250-5.
 23. Müller J, Plaas U, Willeneffer H. Spätergebnisse nach operativ behandelten malleolarfrakturen. *Helv Chir Acta* 1971;38:329-37.
 24. Moran MC. Modified lateral approach to the distal humerus for internal fixation. *Clin Orthop Relat Res* 1997;340:190-7.
 25. Gardner MJ, Griffith MH, Lorich DG. Helical plating of the proximal humerus. *Injury* 2005;36:1197-200.
 26. Wang JP, Shen WJ, Chen WM, et al. Iatrogenic radial nerve palsy after operative management of humeral shaft fractures. *J Trauma* 2009;66:800-3.
 27. Meekers FS, Broos PL. Operative treatment of humeral shaft fractures. The Leuven experience. *Acta Orthop Belg* 2002;68:462-70.
 28. Hannouche D, Ballis R, Raouf A, et al. A lateral approach to the distal humerus following identification of the cutaneous branches of the radial nerve. *J Bone Joint Surg Br* 2009;91:552-6.
 29. Dabezies EJ, Banta CJ II, Murphy CP, et al. Plate fixation of the humeral shaft for acute fractures, with and without radial nerve injuries. *J Orthop Trauma* 1992;6:10-3.
 30. Gerwin M, Hotchkiss RN, Weiland AJ. Alternative operative exposures of the posterior aspect of the humeral diaphysis with reference to the radial nerve. *J Bone Joint Surg Am* 1996;78:1690-5.
 31. Mills WJ, Hanel DP, Smith DG. Lateral approach to the humeral shaft: an alternative approach for fracture treatment. *J Orthop Trauma* 1996;10:81-6.
 32. Laporte C, Thiongo M, Jegou D. Posteromedial approach to the distal humerus for fracture fixation. *Acta Orthop Belg* 2006;72:395-9.
 33. King A, Johnston GH. A modification of Henry's anterior approach to the humerus. *J Shoulder Elbow Surg* 1998;7:210-2.
 34. McIntyre LK, Warner KJ, Nester TA, et al. The incidence of post-discharge surgical site infection in the injured patient. *J Trauma* 2009;66:407-10.

How you can get involved in the CMA!

The CMA is committed to providing leadership for physicians and promoting the highest standard of health and health care for Canadians. To strengthen the association and be truly representative of all Canadian physicians the CMA needs to hear from members interested in serving in elected positions and on appointed committees and advisory groups. The CMA structure comprises both governing bodies and advisory bodies either elected by General Council or appointed by the CMA Board of Directors. The Board of Directors — elected by General Council — has provincial/territorial, resident and student representation, is responsible for the overall operation of the CMA and reports to General Council on issues of governance.

CMA committees advise the Board of Directors and make recommendations on specific issues of concern to physicians and the public. Five core committees mainly consist of regional, resident and student representation while other statutory and special committees and task forces consist of individuals with interest and expertise in subject-specific fields. Positions on one or more of these committees may become available in the coming year.

For further information on how you can get involved, please contact:

Jacqueline Ethier, Corporate and Governance Services
Canadian Medical Association
1867 Alta Vista Drive, Ottawa ON K1G 5W8
Fax 613 526-7570, Tel 800 663-7336 x2249
involved@cma.ca

By getting involved, you will have an opportunity to make a difference.

We hope to hear from you!

