

Cephalic vein cutdown for totally implantable central venous port in children: a retrospective analysis of prospectively collected data

Kyu-Hwan Jung, MD*
Suk-Bae Moon, MD, PhD†

From the *Department of Surgery, Seoul National University Bundang Hospital, Bundang, and the †Department of Surgery, Kangwon National University Hospital, Kangwon National University School of Medicine, Chuncheon, South Korea

Accepted for publication
Feb. 26, 2013

Correspondence to:
S.-B. Moon
Department of Surgery
Kangwon National University Hospital
156 Baekryoung-ro
Chuncheon, 200-722 Korea
sukbae75.moon@gmail.com

DOI: 10.1503/cjs.025512

Background: The jugular vein cutdown for a totally implantable central venous port (TICVP) has 2 disadvantages: 2 separate incisions are needed and the risk for multiple vein occlusions. We sought to evaluate the feasibility of a cephalic vein (CV) cutdown in children.

Methods: We prospectively followed patients who underwent a venous cutdown for implantation of a TICVP between Jan. 1, 2002, and Dec. 31, 2006. For patients younger than 8 months, an external jugular vein cutdown was initially tried without attempting a CV cutdown. For patients older than 8 months, a CV cutdown was tried initially. We recorded information on age, weight, outcome of the CV cutdown and complications.

Results: During the study period, 143 patients underwent a venous cutdown for implantation of a TICVP: 25 younger and 118 older than 8 months. The CV cutdown was successful in 73 of 118 trials. The 25th percentile and median body weight for 73 successful cases were 15.4 kg and 28.3 kg, respectively. There was a significant difference in the success rate using the criterion of 15 kg as the cutoff. The overall complication rate was 8.2%.

Conclusion: The CV cutdown was an acceptable procedure for TICVP in children. It could be preferentially considered for patients weighing more than 15 kg who require TICVP.

Contexte : La dissection de la jugulaire pour la mise en place d'un dispositif d'accès veineux central totalement implantable comporte 2 inconvénients : 2 incisions distinctes sont nécessaires et il y a un risque de multiples occlusions veineuses. Nous avons voulu évaluer la faisabilité d'une dissection de la veine céphalique chez les enfants.

Méthodes : Nous avons suivi de manière prospective des patients soumis à une dissection veineuse pour implantation d'un dispositif d'accès veineux central entre le 1er janvier 2002 et le 31 décembre 2006. Pour les patients de moins de 8 mois, une dissection de la jugulaire externe a d'abord été tentée, sans tentative de dissection de la veine céphalique. Pour les patients de plus de 8 mois, une dissection de la veine céphalique a d'abord été tentée. Nous avons noté l'âge, le poids, l'issue de la dissection de la veine céphalique et les complications.

Résultats : Au cours de la période de l'étude, 143 patients ont subi une dissection veineuse pour pose d'un dispositif d'accès veineux central totalement implantable : 25 avaient moins de 8 mois et 118 avaient plus de 8 mois. La dissection de la veine céphalique a réussi lors de 73 tentatives sur 118. Le poids du 25^e percentile et le poids médian pour les 73 cas réussis étaient de 15,4 kg et de 28,3 kg, respectivement. On a observé une différence significative du taux de réussite associé au critère du poids seuil de 15 kg. Le taux global de complications a été de 8,2 %.

Conclusion : La dissection de la veine céphalique a été une intervention acceptable pour la pose de dispositifs d'accès veineux centraux totalement implantables chez les enfants. Elle pourrait être envisagée chez les patients de plus de 15 kg qui ont besoin d'un dispositif d'accès veineux central implantable.

As the last type of long-term central venous access device developed,¹ the totally implantable central venous port (TICVP) is widely used in children for various purposes, such as chemotherapy or total parenteral nutrition. Although percutaneous central venous access is equally successful in children and adults,² many institutes, like ours, still prefer the cutdown method because of the technical difficulties associated with percutaneous access in children or the lack of facilities.³ The external jugular vein (EJV) or internal jugular vein (IJV) is usually chosen for the cutdown. However, there are 2 shortcomings to the jugular vein cutdown: the need for 2 separate incisions for the port pocket and venous cutdown and the risk for multiple vein occlusions.⁴ Repeated trials and long-term indwelling of the central venous catheter eventually lead to exhaustion of readily and easily accessible vessels. Although the calibre of the cephalic vein (CV) is usually smaller than that of the jugular veins, these disadvantages can be overcome by properly performing a CV cutdown. The jugular vein can be preserved for a period by using the CV first. Most published studies have involved adult patients;⁵⁻⁷ there are few reports on the CV cutdown in children. Our objective was to analyze the results of CV cutdown and to provide guidelines for the CV cutdown in children.

METHODS

Patients

We prospectively enrolled patients who underwent TICVP implantation between Jan. 1, 2002, and Dec. 31, 2006, at the Department of Pediatric Surgery, Seoul National University Children's Hospital, Seoul, Korea. The inclusion criteria were no history of an indwelling central venous catheter and right-side vein (i.e., right internal or external jugular vein, right cephalic vein). The number of patients needing a left-sided approach was small; therefore, for coherence of the comparisons, only right-sided cases were enrolled. All patients were followed prospectively until Mar. 22, 2007. The end-point of follow-up was defined as the time of port removal, regardless of the reasons, or the above end date if the port was still in place.

Technique

We defined an arbitrary cutoff point at 8 months of age. For patients younger than 8 months, we attempted an EJV cutdown initially without attempting a CV cutdown. If this approach failed, an IJV cutdown was the next step. For patients older than 8 months, the CV cutdown was attempted initially. If the CV cutdown failed for any reason, we attempted an EJV and finally an IJV cutdown.

We used 2 types of commercially available products. The Port-a-Cath (5.8-Fr, Deltec Inc.) was used between Jan. 1, 2002, and Dec. 31, 2005. As this brand supports only

5.8-Fr products, we also used Celiste (4.5-Fr or 6.5-Fr, B.Braun Inc.) from Jan. 1, 2006, to the end of this study.

All of the procedures were performed with the patient under general anesthesia. With the patient in a supine position with a roll of the appropriate size under the shoulders, the head was tilted to the left. The incision started from the deltopectoral triangle and ran for 4–5 cm medially, parallel to the inferior margin of the clavicle. The incision was deepened to the fascia overlying the deltoid and pectoralis muscle. The CV was located in the adipose tissue of the deltopectoral groove. The CV was dissected circumferentially for about 1 cm and a nonabsorbable 3–0 silk suture was applied proximally and distally. The distal suture was tied securely, and a hemostat was applied for traction. A fine venotomy was made at the centre of these 2 sutures, and the catheter was passed proximally to a length previously determined. Back bleeding was controlled by ligating the proximal suture without constricting the catheter. The length of the catheter was determined so that the tip was located at the junction of the superior vena cava and right atrium. The position of the tip was confirmed intraoperatively by chest radiograph. We attempted an EJV cutdown in cases where the CV was absent or the calibre of CV was too small for the catheter. An IJV cutdown was the final option when the EJV cutdown also failed. In cases of recurrent misplacement of the catheter (e.g., in the contralateral subclavian vein, in the ipsilateral jugular vein), we abandoned the CV and attempted an EJV approach.

Statistical analysis

We used SPSS software version 12.0 to perform our statistical analyses. We measured the port duration, which we defined as the interval between the port implantation and the end of follow-up. The proportion of the successfully cannulated vessels was measured, and we compared the distribution of age and body weight according to the cannulated vessels using box plots. Statistical power at the 25th percentile body weight on the box plots was used as a cut-off value, and demonstrated a significant difference in the success rate of the CV cutdown; the comparisons were validated using the χ^2 test, with results considered to be significant at $p < 0.05$. We measured the outcomes of the CV cutdown (i.e., successful cannulation, small calibre, recurrent misplacement and CV abandoned, absent CV) and complications.

RESULTS

We enrolled 143 patients (90 boys, 53 girls; 25 younger than 8 mo, 118 older than 8 mo) in the study. The median age at operation was 52 months (range 2 mo to 17 yr). The indications for the port implantation were chemotherapy ($n = 117$; 34 osteosarcoma, 15 retinoblastoma, 10 hepatoblastoma, 11 neuroblastoma, 15 lymphoma, 8 leukemia and 24 other cancers), long-term intravenous antibiotics ($n = 20$; 15 congenital granulomatous disease, 2 severe combined

immunodeficiency and 3 others) and total parenteral nutrition ($n = 6$; 4 tufting enteropathy, 1 Crohn disease and 1 spinal muscular atrophy). The 5.8-Fr Port-a-Cath was used in 120 children, the 4.5-Fr Celiste in 12 and the 6.5-Fr Celiste in 11.

Of the 143 cases, CV accounted for 73 (51%) as the successfully cannulated vessel, EJV for 39 (27%) and IJV for 31 (22%). The median age of patients in the CV group was greater than that of patients in the IJV or EJV groups. A CV cutdown was possible at a minimum age of 8 months. The 25th percentile and the median age of the CV group were 42 months and 122 months, respectively (Fig. 1). The median body weight of patients in the CV group was greater than that of patients in the IJV or EJV groups. The CV cutdown was possible at a minimum body weight of 5.9 kg. The 25th percentile and the median body weight of the CV group were 15.4 kg and 28.3 kg, respectively (Fig. 2).

The outcomes after the CV cutdown are summarized in Table 1. The calibre of the CV vessels was smaller than that of the catheter in 25 (21.2%) patients, and the CV was absent in 10 (8.5%) patients. The CV was abandoned in 10 (8.5%) patients owing to repeated catheter misplacement. The overall success rate for the CV cutdown was 61.9% (73 successes in 118 trials). With the criterion of the 25th percentile body weight (15 kg), the heavier patients had a significantly higher success rate (Table 2).

Failed attempts were further divided according to the 25th percentile body weight. The proportion of small calibre CV was greater in smaller than in larger children; however, this difference was not significant (Table 3).

The median port duration was 568 (range 5–1316) days. There were 6 (8.2%) complications after successful CV

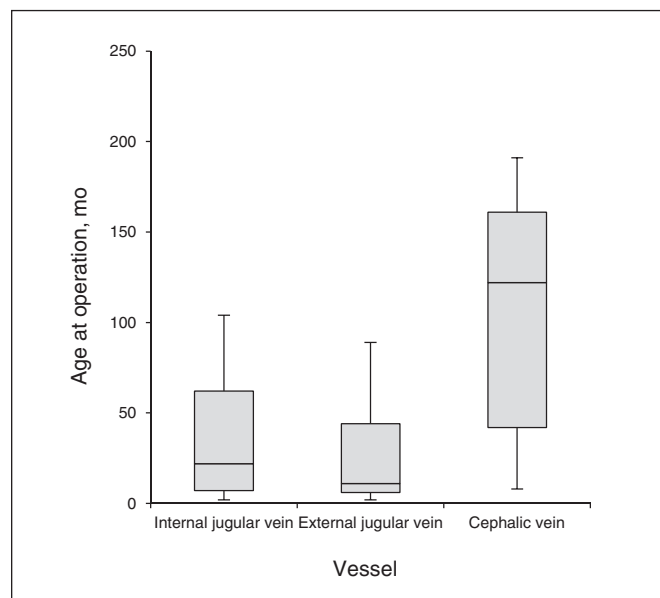


Fig. 1. Distribution of age according to the cannulated vessels for cutdown; 25th percentile and median of 42 months and 122 months.

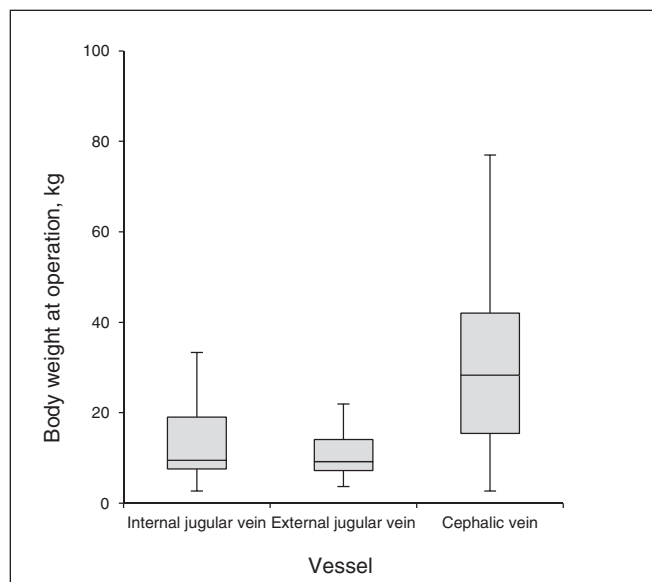


Fig. 2. Distribution of body weight according to the cannulated vessels for cutdown; 25th percentile and median of 15.4 kg and 28.3 kg.

Table 1. Outcome of CV cutdown, $n = 118$

Outcome	Patients, no. (%)
Successful cannulation	73 (61.8)
Small calibre	25 (21.2)
Catheter misplacement and CV sacrificed	10 (8.5)
CV absent	10 (8.5)
Total	118

CV = cephalic vein.

Table 2. Patient number according to weight and the resulting success rate of CV cutdown, $n = 118$

Result	Group; no. (%)*		<i>p</i> value†
	< 15 kg	> 15 kg	
Failure	24 (20.3)	21 (17.8)	0.001
Success	17 (14.4)	56 (47.5)	
Success rate, %	41.4	72.7	

CV = cephalic vein.
*Unless otherwise indicated.
† χ^2 test.

Table 3. Causes of failure further divided by patient weight

Cause	Group; no. (%)	
	< 15 kg	> 15 kg
Small calibre	18 (81.8)	7 (53.8)
Catheter misplacement	4 (18.1)	6 (46.2)

cutdown: catheter-related infection in 4 (5.4%) patients, catheter thrombosis in 1 (1.4%) and arterial cannulation in 1 (1.4%). The calculated catheter-related infection rate was 4 cases for 1935 catheter days, for a rate of 2.1 per 1000 central line days. Only 1 patient experienced an immediate surgical complication. The catheter was inserted through a very small branch of the subclavian artery, which was mistaken to be the CV. Revision surgery was performed using the IJV the next day. Four patients required TICVP revision: 2 for infections, 1 for catheter thrombosis and 1 for arterial cannulation.

DISCUSSION

The goal of this study was to evaluate the feasibility of a CV cutdown for TICVP in children for whom percutaneous techniques are not practical and to improve the success rate of this procedure. It is unusual to use the CV for cutdown to obtain central venous access in adults because a fluoroscopy-guided percutaneous subclavian or IJV approach is commonly safe and effective.⁸ However, the superficial location of the CV in children compared with the adults and the theoretical advantages mentioned earlier, suggest that the CV might provide useful access for cutdown when percutaneous access is not available in children.

Our arbitrary cutoff of 8 months was based on our experience; we have found it almost impossible to place a TICVP through a CV in patients younger than 8 months. We performed the CV cutdown exclusively in patients older than 8 months during the study period and reviewed the clinical variables collected prospectively.

Although the CV cutdown was successful even in a child weighing only 5.9 kg, our results demonstrate that the procedure is more likely to be successful in patients above the 25th percentile for body weight (15 kg). We recommend that this figure be considered the reference value for future procedures.

One disadvantage of the CV cutdown is that the presence of a CV is not predictable before surgery unless a radiological examination is performed preoperatively. Le Saout and colleagues⁹ reported that the CV was anatomically absent in 7% of patients, which is similar to our findings. Although we have not previously performed preoperative ultrasonography, routine preoperative vascular ultrasonography mapping on the CV might detect the absence of CV¹⁰ and prevent unnecessary surgical dissection.

The failure rate of the CV cutdown, including small calibre vessels, catheter misplacement and inability to advance, has been reported to reach 10%–30%.^{11–14} Our failure rate (38.1%) was higher than that of previous studies. However, most of the prior reported results are from adult populations. In our pediatric series, the most frequent cause of failure was small calibre CV. The success rate would be improved by avoiding the small calibre CV on the basis of our reference body weight of 15 kg. The fact that small calibre vessels were a more common cause of failure in small

children (weight < 15 kg) supports this recommendation.

A single-incision approach has a cosmetic advantage over the 2-incision approach that is usually required for IJV or EJV. However, placement of the port in a more disguised location, such as the axilla or inframammary crease, especially in girls, may have other benefits.¹⁵ Therefore, it would be better for the port location to be individualized.

In many reports comparing the fluoroscopy-guided percutaneous subclavian puncture used by interventional radiologists with the CV cutdown procedure performed by surgeons, complication (e.g., pneumothorax, great vessel injuries) rates are consistently lower with surgical methods.^{16,17} Recently, however, there have been numerous reports on the success of the percutaneous technique, either landmark- or ultrasonography-guided, for central venous access in children.^{18,19} Also, as occurred in our study, CV cutdown is not without its complications. The complication rates we observed were in the range of those from other published pediatric series.^{20,21} We observed 1 surgical complication unique to the CV cutdown occurring in an 11-month old patient (9.2 kg in body weight) who was not an appropriate candidate for a CV cutdown. One should be aware of the advantages and disadvantages of each technique before proceeding to the practice.

CONCLUSION

The results of our study showed that CV cutdown for TICVP was a relatively acceptable procedure in children. The more readily accessible veins, the EJV and IJV, can be preserved by using the CV initially. Our findings suggest better outcomes in patients weighing more than 15 kg. The CV cutdown should be considered as an option for central venous access in children.

Competing interests: None declared.

Contributors: S.-B. Moon designed the study. K.-H. Jung acquired the data, which both authors analyzed. K.-H. Jung wrote the article, which S.-B. Moon reviewed. Both authors approved the article for publication.

References

1. Biffi R, de Braud F, Orsi F, et al. Totally implantable central venous access ports for long-term chemotherapy. A prospective study analyzing complications and costs of 333 devices with a minimum follow-up of 180 days. *Ann Oncol* 1998;9:767-73.
2. Cruzeiro PC, Camargos PA, Miranda ME. Central venous catheter placement in children: a prospective study of complications in a Brazilian public hospital. *Pediatr Surg Int* 2006;22:536-40.
3. Cobb LM, Vinocur CD, Wagner CW, et al. The central venous anatomy in infants. *Surg Gynecol Obstet* 1987;165:230-4.
4. Bellasi A, Brancaccio D, Maggioni M, et al. Salvage insertion of tunneled central venous catheters in the internal jugular vein after accidental catheter removal. *J Vasc Access* 2004;5:49-56.

5. Davis SJ, Thompson JS, Edney JA. Insertion of Hickman catheters. A comparison of cutdown and percutaneous technique. *Am Surg* 1984; 50:673-6.
6. Henriques HF III, Karmy-Jones R, Knoll SM, et al. Avoiding complications of long-term venous access. *Am Surg* 1993;59:555-8.
7. Torramadé JR, Cienfuegos JA, Hernández JL, et al. The complications of central venous access system: a study of 218 patients. *Eur J Surg* 1993;159:323-7.
8. Pivoski SP. A prospective analysis of the cephalic vein cutdown approach for chronic indwelling central venous access in 100 consecutive cancer patients. *Ann Surg Oncol* 2000;7:496-502.
9. Le Saout J, Vallee B, Person H, et al. Anatomical basis for the surgical use of the cephalic vein (V. Cephalica). 74 anatomical dissections. 189 surgical dissections. *J Chir (Paris)* 1983;120:131-4.
10. Jennings WC, Turman MA, Taubman KE. Arteriovenous fistulas for hemodialysis access in children and adolescents using the proximal radial artery inflow site. *J Pediatr Surg* 2009;44:1377-81.
11. Wade JC, Newman KA, Schimpff SC, et al. Two methods for improved venous access in acute leukemia patients. *JAMA* 1981;246:140-4.
12. Au FC. The anatomy of the cephalic vein. *Am Surg* 1989;55:638-9.
13. Perry EP, Nash JR, Klidjian AM. Direct cephalic vein cannulation for safe subclavian access. *J R Coll Surg Edinb* 1990;35:218-20.
14. Gallichio MH, Kahn D, Lempert N, et al. Placement of a double lumen silastic catheter for hemodialysis access through the cephalic vein. *J Am Coll Surg* 1994;178:171-2.
15. Pardo I, Rager EL, Bowling MW, et al. Central venous port placement: a comparison of axillary versus anterior chest wall placement. *Ann Surg Oncol* 2011;18:468-71.
16. Di Carlo I, Barbagallo F, Toro A, et al. External jugular vein cutdown approach, as a useful alternative, supports the choice of the cephalic vein for totally implantable access device placement. *Ann Surg Oncol* 2005; 12:570-3.
17. Pivoski SP. External jugular vein cutdown approach for chronic indwelling central venous access in cancer patients: a potentially useful alternative. *World J Surg Oncol* 2004;2:7.
18. Hosokawa K, Shime N, Kato Y, et al. A randomized trial of ultrasound image-based skin surface marking versus real-time ultrasound-guided internal jugular vein catheterization in infants. *Anesthesiology* 2007; 107:720-4.
19. Calvert N, Hind D, McWilliams R, et al. Ultrasound for central venous cannulation: economic evaluation of cost-effectiveness. *Anaesthesia* 2004;59:1116-20.
20. Abbas AA, Fryer CJ, Paltiel C, et al. Factors influencing central line infections in children with acute lymphoblastic leukemia: results of a single institutional study. *Pediatr Blood Cancer* 2004; 42:325-31.
21. Hall NJ, Hartley J, Ade-Ajayi N, et al. Bacterial contamination of central venous catheters during insertion: a double blind randomised controlled trial. *Pediatr Surg Int* 2005;21:507-11.

CJS's top viewed articles*

1. **Research questions, hypotheses and objectives**
Farrugia et al.
Can J Surg 2010;53(4):278-81
2. **Tracheostomy: from insertion to decannulation**
Engels et al.
Can J Surg 2009;52(5):427-33
3. **Blinding: Who, what, when, why, how?**
Karanicolas et al.
Can J Surg 2010;53(5):345-8
4. **Parmacological management of postoperative ileus**
Zeinali et al.
Can J Surg 2009;52(2):153-7
5. **Hardware removal after tibial fracture has healed**
Sidky and Buckley
Can J Surg 2008;51(4):263-8
6. **Preoperative bowel preparation for patients undergoing elective colorectal surgery: a clinical practice guideline endorsed by the Canadian Society of Colon and Rectal Surgeons**
Eskicioglu et al.
Can J Surg 2010;53(6):385-95
7. **All superior pubic ramus fractures are not created equal**
Steinitz et al.
Can J Surg 2004;47(6):422-5
8. **The efficacy and risks of using povidone-iodine irrigation to prevent surgical site infection: an evidence-based review**
Chundamala and Wright
Can J Surg 2007;50(6):473-81
9. **Adhesive small bowel obstruction: epidemiology, biology and prevention**
Attard and MacLean
Can J Surg 2007;50(4):291-300
10. **Topical nifedipine with lidocaine ointment versus active control for pain after hemorrhoidectomy: results of a multicentre, prospective, randomized, double-blind study**
Perrotti et al.
Can J Surg 2010;53(1):17-24

* Based on page views on PubMed Central of research, reviews, commentaries and continuing medical education articles. Updated Jan. 10, 2014.