

Anastomotic salvage after rectal cancer resection using the Turnbull–Cutait delayed anastomosis

Julie Hallet, MD*
 Alexandre Bouchard, MD†‡
 Sébastien Drolet, MD†
 Hélène Milot, MD†
 Emilie Desrosiers, MD†
 Aude Lebrun, MD†
 Roger Charles Grégoire, MD†‡

From the *Division of General Surgery, University of Toronto, Toronto, Ont., †Department of Surgery, Université Laval, Québec, Que., and the ‡Department of Surgery, CHU de Québec (Hôpital Saint-François d'Assise), Québec, Que.

A poster presentation of this study was made at the 2012 Annual American Society of Colon and Rectum Surgeons Meeting, in San Antonio, TX.

Accepted for publication
 May 20, 2014

Correspondence to:
 J. Hallet
 610 University Ave., Room 3-120
 Toronto ON M5G 2M9
 juliehallet@me.com

DOI: 10.1503/cjs.001014

Background: Turnbull–Cutait abdominoperineal pull-through followed by delayed coloanal anastomosis (DCA) was first described in 1961. Studies have described its use for challenging colorectal conditions. We reviewed our experience with Turnbull–Cutait DCA as a salvage procedure for complex failure of colorectal anastomosis.

Methods: We performed a retrospective cohort study from October 2010 to September 2011, with analysis of postoperative morbidity and mortality.

Results: Seven DCAs were performed for anastomotic complications (3 chronic leaks, 2 rectovaginal fistulas, 1 colovesical fistula, 1 colonic ischemia) following surgery for rectal cancer. Six patients had a diverting ileostomy constructed as part of previous treatment for anastomotic complications before the salvage procedure. No anastomotic leaks were observed. All procedures but 1 were completed successfully. One patient who underwent DCA subsequently required an abdominoperineal resection and a permanent colostomy for postoperative extensive colonic ischemia. No 30-day mortality occurred.

Conclusion: Salvage Turnbull–Cutait DCA appears to be a safe procedure and could be offered to patients with complex anastomotic complications. This procedure could be added to the surgeon's armamentarium as an alternative to the creation of a permanent stoma.

Contexte : La résection colique abdominale avec extraction trans-anaïle et anastomose colo-anaïle différée (CAD) fut décrite initialement par Turnbull et Cutait en 1961. Cette intervention a récemment été rapportée pour le traitement des conditions colorectales complexes. Nous avons revu notre expérience avec la CAD comme chirurgie de sauvetage dans le traitement des complications complexes de l'anastomose colo-anaïle de première intention.

Méthodes : Nous avons effectué une étude de cohorte rétrospective entre octobre 2010 et septembre 2011, en analysant la morbidité et la mortalité postopératoires.

Résultats : Sept CAD ont été réalisées en raison de complications anastomotiques (3 fuites anastomotiques chroniques, 2 fistules rectovaginales, 1 fistule colovésicale, 1 ischémie colique) résultant du traitement chirurgical d'un cancer rectal. Six patients avaient subi une iléostomie de dérivation pour fuite anastomotique, dans la période précédant la CAD de sauvetage. À l'exception d'un patient, toutes les procédures se sont soldées en succès. Aucune fuite anastomotique n'a été observée après CAD. Un patient a dû subir une résection abdominopérinéale avec colostomie terminale permanente en raison d'ischémie colique aigue du colon distal après CAD. Aucun décès n'est survenu dans les 30 jours suivant la CAD.

Conclusion : La CAD de sauvetage apparaît comme une intervention sécuritaire qui représente une option thérapeutique valable pour les patients souffrant de complications complexes de fuites anastomotiques colorectales. Cette intervention pourrait s'ajouter à l'arsenal du chirurgien comme alternative à la création d'une stomie permanente.

More than 50 years ago, Turnbull and Cutait described colonic pull-through with delayed coloanal anastomosis (DCA) after rectal resection for the management of rectal cancer, chagasic megacolon and other colorectal conditions.^{1,2} Later developments regarding low rectal dissection and colorectal anastomosis, especially the advent of stapler anastomotic devices, made immediate primary anastomosis the preferred technique. Because it allows adhesion of the serosa of the distal colonic segment to the anal canal, DCA theoretically reduces anastomotic leaks and improves sphincter function preservation.³ It can be used as an ultimate procedure to salvage intestinal continuity in complex anorectal diseases that would otherwise require the construction of a permanent stoma. Use of DCA in this clinical setting has been reported in recent case series with good results.^{4,5} The objective of our study was to review our initial experience with Turnbull–Cutait DCA as a salvage procedure for complex anorectal cases.

METHODS

We conducted a retrospective cohort study to report the technical and clinical results of DCA as a salvage procedure. The Centre Hospitalier Universitaire de Québec (CHUQ) approved this study as a quality of care assessment study.

Selection of participants

From October 2010 to September 2011, all adult patients (≥ 18 years old) consecutively operated for salvage DCA in a single centre (CHUQ) were identified. Salvage DCA included surgeries performed for the treatment of complex anastomotic complications following colorectal anastomosis that failed previous treatment attempts and/or for which a permanent colostomy would be the next step. The DCA procedure was considered on an individual basis for challenging cases for which sphincter amputation and creation of a permanent stoma was otherwise believed to be the only remaining option. The clinical decision to proceed with DCA was made by the attending surgeon; DCA was not attempted for patients with fecal incontinence or anal sphincter hypotonia before the previous treatments (procedures that led to the condition to be potentially salvaged by DCA), as restoration of intestinal continuity was deemed unreasonable. Assessment of this pre-morbid fecal continence function was based on the attending surgeon's judgment when posing the indication for DCA. Informed consent was obtained from all patients, who were offered a permanent stoma as the alternative therapeutic option.

Operative technique

Four colorectal surgeons performed all DCAs. The DCA procedure was performed in 2 surgical stages: the rectal

resection and exteriorization of the proximal colon followed by a DCA several days later. For the first stage, the patient is in the lithotomy position under general anesthesia, and an abdominal approach is used. This part of the procedure is adapted to the modified anatomy that resulted from the previous rectal surgery, including previous splenic flexure mobilization. The distal remaining colon is mobilized enough to allow it to reach the anal verge without tension, and the neorectum is dissected down to the pelvic floor. Then, a perineal transanal approach is used to transect the distal neorectum at the level of the dentate line below the diseased segment and the previous anastomosis. The specimen is pulled through the anus. Mucosectomy is not routinely performed, and the anal sphincters are left intact. Proximal transection is performed with a linear stapler in order to resect the part of the neorectum involved in the anastomotic complication process. This leaves an exteriorized colonic stump of descending colon measuring 6–8 cm. This stump is then secured to the perianal skin with 2 sutures. A small venting hole is created by removing a corner of the staple line to allow for decompression of the stump (Figs. 1 and 2). The stump is enveloped in saline-soaked gauzes, and its viability is visually assessed daily when changing dressings. Final anastomosis is planned to take place 7–10 days later. During that interval, patients are fully ambulatory and resume a low-residue diet when judged appropriate.

During the second stage of the procedure, the colonic stump is sectioned at the level of the anal verge (Fig. 3). In order to preserve the adhesions between the colonic serosa and the anal canal, no dissection is made into this plane. A handsewn coloanal anastomosis is then performed at the level of the anal verge using interrupted absorbable sutures (Fig. 4).

Outcomes

The primary outcomes were technical feasibility (completed DCA) and 30-day morbidity and mortality. Secondary outcomes included rate of surgical reintervention and length of stay in hospital.

Data were prospectively captured using a standardized form. We collected information regarding demographics (age, sex, comorbidities, American Society of Anesthesiologists [ASA] score), investigation and details of previous procedures. Operative details (duration, estimated blood loss, laparoscopic v. open); delay between the 2 stages of DCA; length of stay after the first stage; postoperative complications, including anastomotic events (leaks, pelvic abscess, colonic stump necrosis); and 30-day mortality were recorded. The surgeon digitally assessed the integrity of the anastomosis at discharge, with other exams performed according to the clinical evolution. All patients had a clinical visit scheduled 3–4 weeks after discharge.

Statistical analysis

Observational description was undertaken. We conducted statistical analyses using XLSTAT version 2011.5 (Addinsoft SARL) for Excel (Microsoft). Continuous data are expressed as means with standard deviation (SD) or medians with interquartile range (IQR), as deemed appropriate, and categorical data are reported as proportions (no., %).

RESULTS

Seven patients underwent salvage DCA. Demographic and clinical data are presented in Table 1.

Three men and 4 women with a mean age of 60.3 (range 49–74) years underwent DCA for coloanal anastomosis salvage. Indications for surgery are detailed in

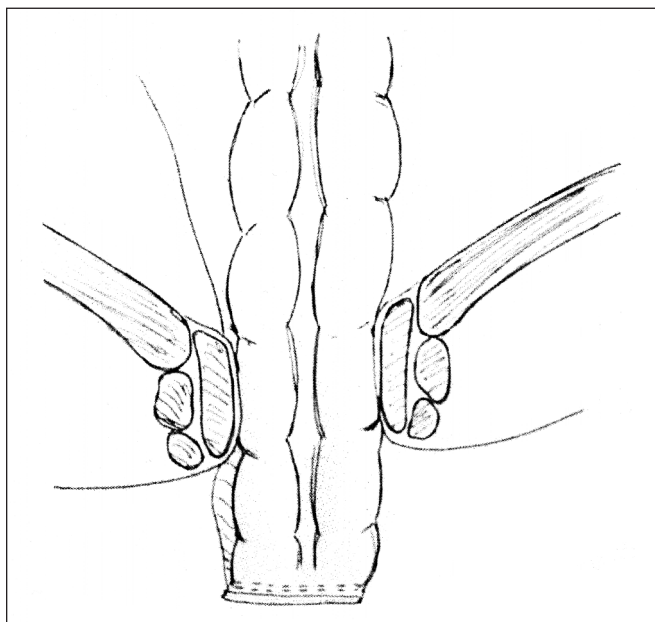


Fig. 1. Phase 1: After mobilization, the specimen is pulled through the anus and transected proximally.

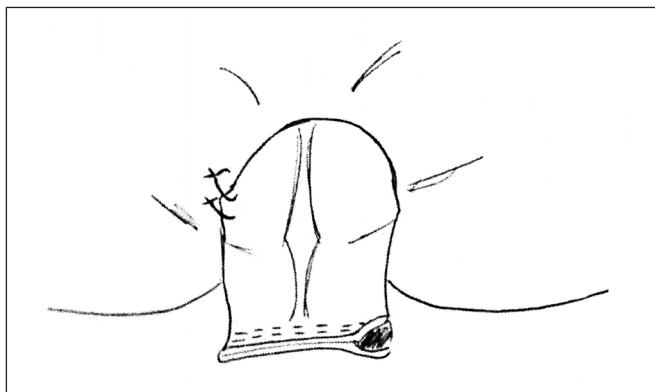


Fig. 2. Phase 1: The colonic stump is secured to the perianal skin, and a venting hole is created.

Table 1. All were complications of a colorectal anastomosis that persisted and/or worsened despite previous treatments, including initial fecal diversion, multiple attempts at transrectal drainage or advancement flaps for fistulas. One patient (patient B) presented with severe sepsis due to colonic ischemia proximal to his anastomosis 9 days after his initial surgery. At the time of emergent surgery he was not stable enough to undergo repeated immediate anastomosis. Thus, resection of the ischemic colon and DCA were performed. The last patient (patient G) was referred to our institution for anastomotic rescue after a misfire of the

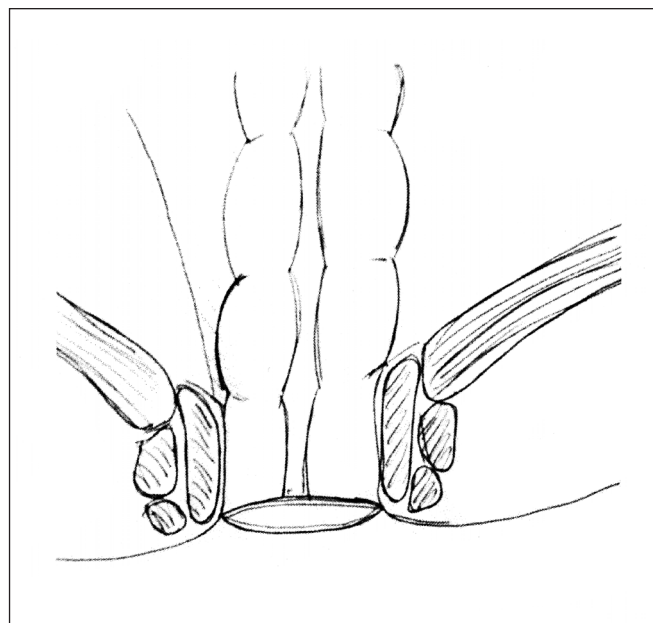


Fig. 3. Phase 2: The colonic stump is sectioned at the level of the anal verge.

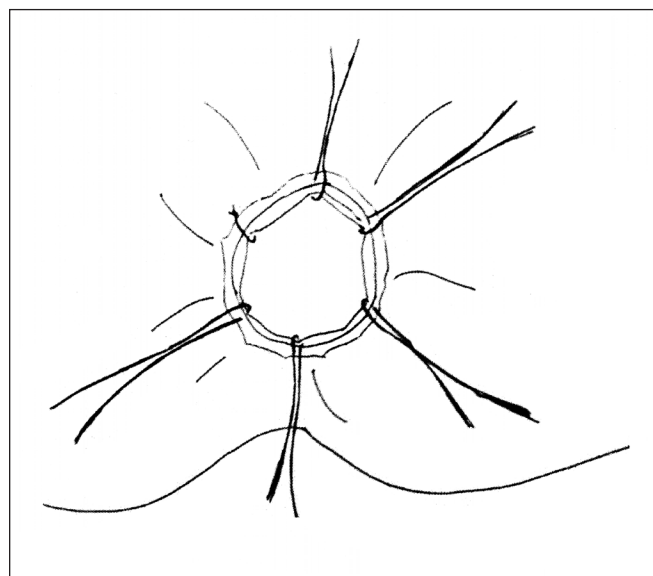


Fig. 4. Phase 2: Hand-sewn coloanal anastomosis is created with interrupted absorbable sutures.

stapling device during low colorectal anastomosis; the referring general surgeon was unable to perform a handsewn anastomosis. In total, 6 patients already had a diverting ileostomy from previous surgical treatment attempts of the anastomotic complication.

Median operative duration for the first stage was 145 (IQR 120–280) minutes, with a median estimated blood loss of 685 (IQR 563–2400) mL. A diverting loop ileostomy was created in the patient who did not have a previous one because of the complexity of the case.

The second stage was undertaken at a mean of 10 days after the first stage. This part of the procedure took less than 15 minutes in 6 patients; the other patient (patient E) had a reversal of her loop ileostomy at the same time.

Six of 7 (85.7%) DCA procedures were completed. One patient needed an abdominoperineal resection with a permanent colostomy post-DCA after extensive colonic ischemia.

Outcomes are detailed in Table 2. Five (62.5%) patients experienced complications: 2 had urinary tract

Table 1. Demographic and clinical characteristics of the 7 patients who underwent salvage DCA

Patient	Sex	Age, yr	ASA score	Initial diagnosis and surgery	Indication for DCA	Previous treatment attempts	Previous stoma
A	Female	61	1	Distal rectal cancer (pT1N0M0) Laparoscopic LAR	Large rectovaginal fistula with cloaque (subtotal anastomotic disruption) Anal stricture	Noninvasive anal dilations Transrectal drainage	None
B	Male	62	2	Distal rectal cancer Neoadjuvant brachytherapy Laparoscopic LAR	Distal colonic ischemia on POD 9, with severe sepsis	None DCA at the time of reintervention for ischemia.	Loop ileostomy at initial surgery
C	Female	49	1	Distal rectal cancer Neoadjuvant chemoradiotherapy Laparoscopic LAR	Anastomotic leak (> 180° disruption) on POD 6 Chronic pelvic abscess	Multiple transrectal drainage	Loop ileostomy at initial surgery
D	Female	64	2	Distal rectal cancer Neoadjuvant chemoradiotherapy Open LAR	Rectovaginal fistula	Rectal advancement flap Fecal diversion	Loop ileostomy
E	Female	74	2	Mid-rectal cancer Open LAR	Anastomotic leak (> 180° disruption) on POD 6	Transrectal drainage	Loop ileostomy at initial surgery
F	Male	51	2	Mid-rectal cancer Neoadjuvant chemoradiotherapy Open LAR	Colovesical fistula	Fecal diversion Noninvasive anal dilations	Loop ileostomy
G	Male	61	2	Mid-rectal cancer Neoadjuvant chemoradiotherapy Laparoscopic LAR	Failure to initially perform CAA (misfired stapler) — referral to tertiary centre	Failed attempt at initial handsewn CAA	Loop ileostomy at initial surgery

ASA = American Society of Anesthesiologists classification; CAA = coloanal anastomosis; DCA = delayed coloanal anastomosis; LAR = low anterior resection; POD = postoperative day.

Table 2. Postoperative outcomes for the 7 patients who underwent salvage DCA

Patient	Time to oral intake, d	Interval between DCA stages	Reoperation	Postoperative course	Post-DCA length of stay, d	Follow-up, d	Stoma reversal, time interval	Anastomotic leak*
A	3	12	No	Urinary tract infection	12	427	Awaiting reversal surgery	No
B	10	8	No	Ileus	12	521	Yes, 217 d	No
C	2	11	No	Pelvic abscess	13	435	Yes, 597 d	No
D	3	9	No	Urinary tract infection	17	292	Refused stoma reversal	No
E	2	11	No	Uneventful	17	254	Yes, 154 d	No
F	1	8	Yes: APR	Colonic stump necrosis	14	184	NA	—
G	3	12	No	Uneventful	12	265	Yes, 193 d	No

APR = abdominoperineal resection; DCA = delayed colonic anastomosis; NA = not applicable.

*Radiological assessment of anastomotic leak was undertaken based on clinical evolution of patients.

infections, 1 had ileus, 1 had colonic stump necrosis and 1 had a pelvic abscess. No major cardiorespiratory events and no 30-day mortality were observed. Oral intake was resumed by a mean of 3.5 ± 3.3 days after the first stage of DCA and 1.6 ± 0.8 days after the second stage. On last follow-up, 4 patients had a stoma reversal, 1 patient was awaiting reversal surgery and another patient refused to have his stoma closed. The median time to stoma reversal was 205 (range 143–597) days. At a median of 274 (IQR 258.5–394) days, no anastomotic leak was noted based on clinical evaluation, and 1 pelvic abscess (12.5%) occurred in a patient with a chronic cavity at the time of DCA. The mean length of stay following the first stage of DCA was 13.9 ± 2.3 days.

DISCUSSION

We report our initial experience with the use of Turnbull–Cutait DCA as a salvage procedure in patients with complex anorectal conditions. Since reports by Cutait himself,^{2,3} to our knowledge, the present study involves the first reported cohort undergoing DCA specifically for salvage purposes. Our patients had a previous low anterior resection with coloanal anastomosis and experienced severe anastomotic complications despite multiple treatment attempts. Salvage DCA was considered for the most challenging cases as a last resort before sphincter amputation and permanent colostomy. Indeed, in these patients a permanent stoma was considered to be the only other option. We successfully completed DCA in 6 patients, and intestinal continuity was restored in 4. One patient had an abdominoperineal excision for proximal colonic ischemia after DCA. In this patient, the clinical situation and the remaining length of the colon precluded a new attempt at DCA.

Most patients experienced a relative ischemia and, sometimes, necrosis of the exteriorized colonic stump. We believe that the inevitable radial pressure exerted on the colonic stump by the sphincter complex likely leads to a relative ischemia of the exposed colon. Despite this phenomenon, the colon was found to be viable at the level of the anal verge at the time of transection during the second stage of the procedure. Therefore, the anastomosis could be performed in 6 of 7 patients. The patient who had extensive colonic ischemia that precluded the second stage of DCA and required a permanent colostomy was an obese man (body mass index 37) with a narrow pelvis. Technical difficulties associated with bringing the proximal colon through the anus were experienced at the initial stage, and this may have compromised the blood supply of the distal colon. With this exception, our experience indicates that a distal colon segment of sufficient length can be obtained for safe pull-through in most

patients, as long as time is taken to perform a generous colon mobilization during the abdominal portion of the procedure. In this very specific population of patients in whom initial anastomosis has failed, the need to exteriorize a segment of distal colon through the anal canal to perform DCA appears to be an interesting strategy to ensure truly tension-free salvage anastomosis. Finally, we should mention that rectal prolapse resulting from DCA has not been an issue in our experience, nor has it been reported in the current literature on this technique.⁶

Once considered surgical legacy, Turnbull–Cutait DCA has recently been reintroduced in surgical practice. Recent experience with DCA has been reported by only a few centres in France and by the Cleveland Clinic in the United States.⁶ In 1996, Baulieux and colleagues⁴ reported on the use of DCA for the treatment of low rectal carcinoma that received radiation therapy. Of 24 patients who underwent DCA without fecal diversion, no anastomotic leak was reported, and 1 patient experienced anastomotic stenosis. In 2011, Jarry and colleagues⁷ reported 2% leak and 6% pelvic abscess rates with DCA performed for primary management of distal rectal carcinoma. The only other cohort considering DCA for salvage purposes was reported by Remzi and colleagues⁵ as a prospective case-matched study comparing a mixed cohort of 44 patients undergoing salvage and primary DCA to 88 patients undergoing immediate anastomosis. Significant decreases in anastomotic leaks (3% v. 7%; $p < 0.05$) and pelvic abscess (0% v. 5%; $p < 0.05$) were observed with DCA. In the present cohort, we achieved similar success (85.7%) and leak rates (none). One patient had a pelvic abscess drained percutaneously, and 1 needed an APR because of colonic stump necrosis. Because this is a highly selected population, global morbidity remains high. Four of our patients initially presented with acute or chronic sepsis, which compares to rates reported in previous series.^{5,8}

Most patients remained ambulatory and were able to resume a low-residue diet between the 2 stages of the procedure. A systematic review of the literature on DCA revealed that the mean interval between the 2 stages of the procedure is 7 (range 5–10) days.⁶ In the present study, the mean time between the 2 stages was 10 (range 8–12) days. While we aimed to perform the second stage after 7 days, we encountered difficulties related to access to the operating room whereby many cancellations occurred owing to human resources issues. All patients in our cohort had a diverting ileostomy. Some studies have reported good success with DCA without fecal diversion.^{7–9} However, that was in elective settings, such as resection for primary treatment of rectal cancer. In a salvage situation, most patients require diversion of fecal stream to help with

the control of local sepsis before treatment with DCA. Moreover, one could argue that fecal diversion may not be required at the initial stage of DCA once the initial sepsis is controlled. However, we felt our approach was safer given the magnitude of the damages in the pelvis. Remzi and colleagues⁵ also reported their experience with the use of routine fecal diversion when performing DCA with salvage purposes and achieved a 7% leak rate. Fecal diversion for the treatment of complex anastomotic complications is often used, and its combination with DCA in our series reflects the selection of patients with complex cases. At this point, it is difficult to ascertain whether fecal diversion is essential in these complex situations, although it appears prudent to use it liberally.

Few data are available on the functional outcomes after DCA. As the procedure results in a straight coloanal anastomosis, one would expect worse initial function. Colonic J-Pouch has been demonstrated to offer less daily bowel movement and fecal urgency after rectal resection than straight coloanal anastomosis.¹⁰ Given the need to pull a colonic segment straight through the anal canal, creation of such a reservoir is not possible with DCA, especially in salvage cases where one has to deal with the previously resected colon and modified anatomy. Recent data suggest that the straight neorectum can adapt over time to achieve similar function as a reservoir after 2 years.^{11,12} Comparison of functional issue after DCA is difficult because no assessment tool has been consistently used in previous series. In one study, Remzi and colleagues⁵ did not observe a significant difference on the mean Wexner score between DCA and immediate anastomosis (10.6 v. 12.2; $p = 0.09$). Overall, fair to good function has been suggested with DCA, depending on the scale used for measures.^{5,7-9} Unfortunately, no functional data were prospectively collected in our cohort. None of our patients required a new fecal diversion for poor function. In this population compared to patients having elective resection without anastomotic failure, functional results may not be optimal. However, considering that the traditional alternative treatment option for these patients involves the creation of a permanent stoma, salvage DCA offers an opportunity to maintain intestinal continuity and sphincter function that would otherwise be nonexistent. Owing to the scarring repercussions of a stoma, in our experience, many patients are willing to accept decreased functional results in order to avoid a permanent stoma.

The patients in our cohort were highly selected on an individual basis. Notwithstanding the benefit of DCA to maintain fecal function in challenging situations, it is not suited to all patients. Patients with potential contraindications include those for whom return of proper fecal continence is not anticipated

despite restoring intestinal continuity (e.g., patients with fecal incontinence before the anastomotic complication, with sphincter hypotonia or with such a devastated pelvic floor that function of the sphincter complex is compromised). A detailed history and physical examination are needed to evaluate the potential for fecal continence recuperation. To be technically feasible, DCA requires sufficient length of remaining distal colon to reach the anal verge without tension or risk of devascularisation. As the anal canal exerts pressure on the pulled-through colon, a very long anal canal could also be an issue depending on the length and vascularization of distal colon available for mobilization. Thus, careful review of the chart, previous operating report and current imaging are essential to appreciate the anatomy and plan for DCA.

Limitations

Our study has several limitations. Its descriptive nature and its small sample size cannot be overlooked. Patients were selected at the discretion of the attending surgeon without specific criteria; therefore, selection bias is possible. Because the patients selected for salvage DCA were unique and would have otherwise undergone permanent stoma creation, it was difficult to identify a proper sample of patients to match for comparison. Indeed, the control group would have differed either in the indication for surgery (nonsalvage) or in the procedure and expected outcomes (permanent stoma creation). This observational cohort details the use of DCA for very challenging cases to allow for individual appreciation of the feasibility and benefit of the technique. We acknowledge that the occurrence of anastomotic leaks was not systematically assessed by routine postoperative radiology exams and that subclinical leaks may then have been missed. Follow-up remains short, and more investigation will be needed to assess functional results. Although this study represents a small number of patients, to our knowledge, it is the first reported experience of the use of DCA for salvage purposes outside of the Cleveland Clinic series.⁵ Our study shows that DCA could be considered as an option for challenging complications of colorectal anastomosis and offers patients a chance at maintaining their anal sphincter function.

CONCLUSION

Turnbull–Cutait DCA appears to be safe as a salvage procedure for complex anastomotic failure following colorectal anastomosis. This remains a difficult procedure, especially in patients with previous pelvic sepsis. However, the procedure allowed for preservation of intestinal continuity

for the majority of patients in our cohort. Data regarding functional outcomes and long-term follow-up are needed.

Competing interests: None declared.

Contributors: J. Hallet, A. Bouchard and R. Grégoire designed the study. J. Hallet, H. Milot, E. Desrosiers and A. Lebrun acquired the data, which J. Hallet, A. Bouchard, S. Drolet, E. Desrosiers and R. Grégoire analyzed. J. Hallet, A. Bouchard and S. Drolet wrote the article, which all authors reviewed and approved for publication.

References

1. Turnbull RJ, Cuthbertson F. Abdomino rectal pull-through resection for rectal cancer and for Hirschprung's disease. *Cleveland Clin Q* 1961;(28):109-15.
2. Cutait DE, Figlioni FJ. A new method of colorectal anastomosis in abdominoperineal resection. *Dis Colon Rectum* 1961;4:335-42.
3. Cutait DE. Prevention of pelvic complications in pull-through operations for cancer and benign lesions. *Proc R Soc Med* 1970; (63):121-8.
4. Baulieux J, Adham M, Nasser Y, et al. Anastomose colo-anele différée sans colostomie temporaire de protection pour cancer bas du rectum après radiothérapie pré-opératoire. *Lyon Chir* 1996;92:87-93.
5. Remzi FH, Gazzaz El G, Kiran RP, et al. Outcomes following Turnbull-Cutait abdominoperineal pull-through compared with coloanal anastomosis. *Br J Surg* 2009;96:424-9.
6. Hallet J, Milot H, Drolet S, et al. The clinical results of the Turnbull-Cutait delayed coloanal anastomosis: a systematic review. *Tech Coloproctol* 2014;18:579-90.
7. Jarry J, Faucheron JL, Moreno W, et al. Delayed colo-anal anastomosis is an alternative to prophylactic diverting stoma after total mesorectal excision for middle and low rectal carcinomas. *Eur J Surg Oncol* 2011;37:127-33.
8. Facy O, Lagoutte N, Jambet S, et al. Anastomose colo-anele différée sans stomie de dérivation après résection antérieure basse du rectum. *J Chir (Paris)* 2009;146:458-63.
9. Olagne E, Baulieux J, la Roche de E, et al. Functional results of delayed coloanal anastomosis after preoperative radiotherapy for lower third rectal cancer. *J Am Coll Surg* 2000;191:643-9.
10. Heriot AG, Tekkis PP, Constantinides V, et al. Meta-analysis of colonic reservoirs versus straight coloanal anastomosis after anterior resection. *Br J Surg* 2006;93:19-32.
11. Joo JS, Latulippe JF, Alabaz O, et al. Long-term functional evaluation of straight coloanal anastomosis and colonic J-pouch: Is the functional superiority of colonic J-pouch sustained? *Dis Colon Rectum* 1998;41:740-6.
12. Ho Y-H, Seow-Choen F, Tan M. Colonic J-pouch function at six months versus straight coloanal anastomosis at two years: randomized controlled trial. *World J Surg* 2001;25:876-81.