

Rheumatology: 1. Is it arthritis?

Stephanie Ensworth

Case 1

A 29-year-old woman consults her physician 2 months after the birth of her second child because she woke one morning with pain and swelling in her wrists, small joints of the hands, knees, ankles and balls of the feet. She is stiff for an hour after arising and is extremely fatigued but has no other associated symptoms or preceding illnesses. She had reported similar, milder symptoms after her first pregnancy, but the joint pains and stiffness disappeared after 1 month of ibuprofen (400 mg, 4 times daily) treatment. Blood tests reveal a high level of rheumatoid factor and antinuclear antibodies.

Case 2

A 69-year-old woman reports that in the year since her last checkup she has had progressive pain in the joints of her fingers, at the base of her thumbs and in her knees, and she has bunions. The pain is worse with activity. She has had minimal (20 min) morning stiffness and no joint swelling, although the small joints of her fingers and the bunions have been developing increasing deformities with deviations and bony enlargements. She recalls that her mother had gnarled fingers at an older age. Her complete blood count and erythrocyte sedimentation rate (11 mm/h) are normal.

Case 3

A 40-year-old father of 3 has recently become unable to work as a construction worker because of chronic low-back pain and stiffness, which began when he was in his early 20s. He consults his physician for the first time because his livelihood is in jeopardy. Recently, his thoracic spine between the shoulder blades has been stiff, his shoulders have been painful and 1 knee has been swollen. Otherwise, he is well and blood tests are normal.

Case 4

A 50-year-old school teacher has a 3-year history of progressive vague low-back pain associated with pain in the muscles, bones and joints of the arms, legs, neck and chest, sparing the hands. All of the pains are exacerbated by activity. She has some morning stiffness but denies swollen joints. In addition, she has progressively marked fatigue and episodic diarrhea, alternating with constipation. She now feels unable to work because of pain and fatigue. Blood tests and radiographs of her lumbar spine are normal.

These cases demonstrate the diversity of rheumatic diseases and their potential impact on society. Rheumatology is not synonymous with geriatric medicine — people of all ages can be affected. Some diseases are inflammatory and some are not. For inflammatory causes of arthritis especially, prompt diagnosis and the early initiation of appropriate treatment is increasingly recognized as the standard of care that is required. Appropriate early treatment may alter the course of many of the systemic inflammatory disorders so that damage, disability and the incidence of premature death are reduced. Some rheumatic disorders are curable, while others can enter a long-term remission with the appropriate treatment.

Musculoskeletal complaints are among the most common reasons people seek medical attention from a primary care physician and are the number 1 cause of long-term disability and inability to work in Canada.¹⁻³ Many rheumatic disorders strike people in their most productive years. Yet, of all organ-system disorders, many physi-

Review

Synthèse

Dr. Ensworth is Clinical Assistant Professor of Medicine, Mary Pack Arthritis Centre and the Arthritis Research Centre of Canada, Vancouver, BC.

This article has been peer reviewed.

CMAJ 2000;162(7):1011-6

This series has been reviewed and endorsed by the Canadian Rheumatology Association.

The Arthritis Society salutes CMAJ for their extensive series of articles on arthritis. The society believes that this kind of information is crucial to educating physicians about this devastating disease.

Series editor: Dr. John M. Esdaile, Professor and Head, Division of Rheumatology, University of British Columbia, and Scientific Director, Arthritis Research Centre of Canada, Vancouver, BC.

April 4, 2000
Table of Contents

icians report that they feel the least comfortable treating musculoskeletal complaints.¹⁻³

The diagnosis of rheumatic disease is based primarily on the patient's history and physical examination. Sophisticated serologic tests can support a clinical diagnosis, but more often they mislead the unwary; if the serology does not match, the clinical impression prevails. Similarly, imaging only supports or confirms the clinical impression. Tests will often be normal early in the course of a rheumatic disease, as illustrated in 3 of the 4 cases previously described.

After completing a thorough musculoskeletal history and physical examination, the physician can focus on a limited differential diagnosis. To evaluate joint pain and arrive at a diagnosis the following questions should be answered:

- Is the pain articular or nonarticular?
- Is the problem inflammatory or noninflammatory?
- Is the problem acute or chronic?
- What is the pattern of the joints involved?
- Are there any associated symptoms or signs?

Is the pain articular or nonarticular?

The first and most important step in making a musculoskeletal diagnosis is to determine if a complaint of "joint pain" is truly an articular (or joint) problem or if the problem is actually in the tissues surrounding the joint.

An articular problem usually indicates arthritis of some sort. Exceptions to this include nonarthritic intra-articular problems such as a meniscal injury in the knee, an intra-articular loose body, intra-articular fractures (including avascular necrosis of the bone), hemarthroses and extremely rare joint tumours. Nonarticular problems, which arise from the surrounding structures, include bursitis, tendonitis, enthesitis (inflammation at sites of ligament and

tendon attachment to bone), ligament injuries and muscle problems, including fibromyalgia.

To differentiate between articular and nonarticular problems, the physician should begin by asking the patient to identify the exact site of pain by pointing to the painful area. This is particularly helpful in assessing complaints of what a patient will call "hip pain" or "ankle pain." When complaining of hip pain, most patients are actually experiencing a nonarticular hip problem and, when asked, will point to the region of the greater trochanter (trochanteric bursitis or fibromyalgia tender point) or the buttock (often

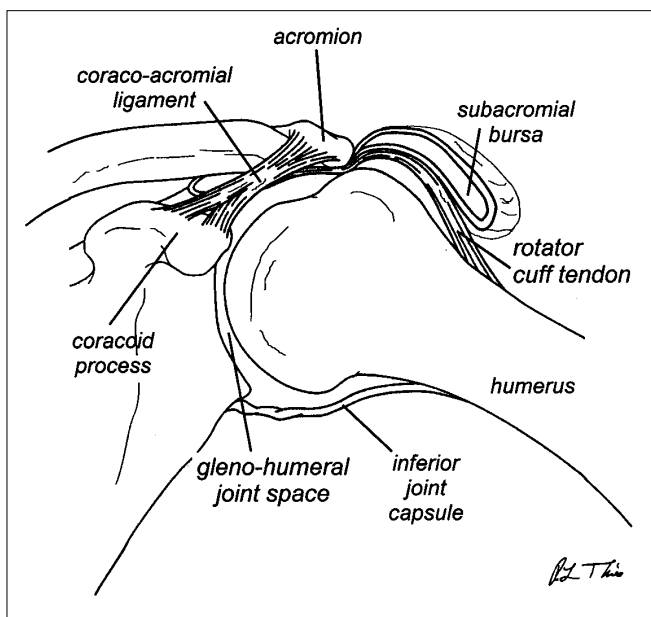


Fig. 1: Glenohumeral joint of the shoulder showing ligamentous and musculotendinous attachments.

Table 1: Differentiating articular from nonarticular pain on physical examination

Physical feature	Articular (capsular pattern)	Nonarticular (noncapsular pattern)
Ranges of motion in the joint	Restricted more or less equally throughout all ranges of motion	Asymmetrically restricted (e.g., flexion may be restricted, but extension may be normal)
Active (performed by patient) v. passive (performed by physician) ranges of motion	Restrictions in active ranges of motion will be similar to restrictions in passive ranges of motion	Restrictions in active and passive ranges of motion will be different
Pain	Pain or stress pain (pain at end-range of motion) on testing all ranges of motion	Pain or stress pain only on testing some ranges of motion
Tenderness on palpation	Over the joint line	In periarticular areas
Timing of the report of pain	When the joint is moved through all ranges of motion When the joint is palpated	When the joint is moved through some ranges of motion May be reported after the joint has been palpated or moved
Swelling (if present)	Diffuse	Localized, defined area, such as in a bursa or around a tendon
Special tests (isometric resisted muscle testing)	Negative or positive for all periarticular muscles tested	Positive for 1 particular muscle group (tendinitis and enthesitis) May be positive for more than 1 periarticular muscle group (bursitis and fibromyalgia) but will not give all-negative or all-positive pattern, as in articular problem

a low-back disorder). A true hip-joint problem causes anterior groin pain. True ankle-joint pain is felt along the anterior tibiotalar joint line. Most patients with Achilles tendinitis or medial or lateral malleolar pain will complain of ankle pain, but will point to 1 of these nonarticular structures when asked to identify the exact site of pain.

Second, the physician should determine which ranges of motion are painful or restricted. A patient with a true joint problem will describe pain or restriction for all ranges of motion tested in the specific joint and will describe reaching the limit of joint motion as the most painful (often called stress pain). A patient with a nonarticular problem will describe pain or restriction for only some of the ranges of motion of that particular joint, and reaching the limit of the range may not necessarily be associated with the most pain.^{4,5}

This information is especially helpful in evaluating a painful shoulder — a joint that has many periarticular structures (e.g., bursas, rotator cuff and other tendons and prominent periarticular muscles). A patient with true glenohumeral joint arthritis will describe pain or restriction in all ranges of motion of the shoulder (i.e., elevation, abduction, adduction, internal rotation and external rotation) and will describe the pain as most severe on reaching the limits of motion. A patient with a periarticular shoulder problem (e.g., subacromial bursitis or tendinitis of 1 of the rotator cuff tendons) will describe pain or restriction on performing some shoulder motions, especially abduction (the so-called “painful arc”) and usually internal rotation, but external rotation will be normal. Some shoulder periarticular problems will be associated with the most pain through the midrange of motion, and the pain will ease off as the limits of joint range are reached. For example, supraspinatus tendinitis will cause pain on arm abduction between approximately 60° and 120°, but at full elevation the pain will actually decrease. Fig. 1 shows the glenohumeral joint of the shoulder with the ligamentous and musculotendinous attachments (including rotator cuff tendons), joint capsule and subacromial bursa.

Physical examination is also important in differentiating articular from nonarticular pain (Table 1). True joint pathology is described as producing a capsular or articular pattern in the reduction of passive joint ranges of motion (i.e., the passive ranges of motion of the particular joint being examined are reduced approximately equally). Nonarticular problems produce a noncapsular or nonarticular pattern in the reduction of passive ranges of motion of the joint (i.e., 1 or several of that joint’s ranges of motion are reduced much more than others).⁵ The only exceptions to

this rule are the glenohumeral joints and hip joints. In the glenohumeral joint an early or mild capsular pattern, a true joint problem, will reduce external rotation before other passive ranges of motion in the joint. In the hip joint, however, internal rotation will be reduced before other passive ranges of motion.⁵

Is the disorder inflammatory or noninflammatory?

The second most important step in arriving at a correct diagnosis that will form the basis of treatment is determining if the disorder is inflammatory or noninflammatory. A patient with inflammatory articular problems will have a history of 1 or all of the following: joint swelling, warmth and, on the rare occasion, redness (e.g., a septic joint is red, but a rheumatoid joint is not). These signs are not associated with noninflammatory articular problems. An inflamed joint will be stiff in the morning for at least 30 minutes and after periods of rest during the day (gelling); noninflammatory forms of arthritis such as osteoarthritis will not be associated with morn-

ing stiffness (or the morning stiffness will last less than 30 minutes), and gelling will last no more than a few minutes.

The only exception to this rule is the nonarticular noninflammatory condition, fibromyalgia, which is associated with widespread nonarticular pain in bones, muscles, joints, neck and back; normal ranges of motion; exacerbation of pain with exercise, especially after exercise; and nonrestorative sleep disorder. For reasons that are not understood, some patients with fibromyalgia report significant durations of morning stiffness or stiffness that persists all day. A nonarticular problem might be described as swollen, hot or red (e.g., septic olecranon or prepatellar bursitis) but not stiff. The physical features that differentiate inflammatory articular conditions from noninflammatory articular problems and inflammatory nonarticular problems are listed in Table 2.

Is the disorder acute or chronic?

The third step in evaluating a joint disorder is to determine whether the problem is acute (< 6 weeks in duration) or chronic (> 6 weeks duration). The main causes of acute inflammation of the joint include septic arthritis, injury (hemarthroses) and crystal arthritis. Any of the chronic forms of arthritis might also result in an acutely inflamed joint, but the chronic forms would be considered only after excluding sepsis, injury and crystal arthritis. The diagnostic

Key points

- Rheumatic diseases are diverse, affect people of all ages and have a significant impact on society.
- Musculoskeletal problems are the number 1 cause of long-term disability in Canada and the second-most common reason people consult a primary care physician.
- Early diagnosis and treatment can alter the course of many of these diseases, particularly the most severe.

factors to be considered in an acute inflammatory nonarticular problem (e.g., bursitis, tendinitis) are similar to those for acute arthritis.

Chronic inflammatory arthritis, bursitis, tendinitis and enthesitis support a diagnosis of 1 of the chronic systemic inflammatory disorders (i.e., rheumatoid arthritis, 1 of the seronegative spondyloarthropathies, 1 of the crystal arthropathies or a connective tissue disorder). Non-inflammatory joint problems (e.g., osteoarthritis) are usually chronic in nature.

What is the pattern of the joints involved?

The fourth step in evaluating a joint complaint is to determine the pattern of the joints affected — their symmetry, size and number — and whether the axial skeleton is involved.

- Are the affected joints symmetrically involved (e.g., is there arthritis in both wrist joints or just 1)?
- Are large joints (shoulders, hips, knees) or small joints (wrist, metacarpophalangeal, proximal interphalangeal, distal interphalangeal, ankle, midtarsal, metatarsophalangeal joints) affected?
- How many joints are affected? This step is referred to as “the joint count.” Monoarticular refers to the involvement of 1 joint, oligoarticular, to the involvement of 2–4 joints, and polyarticular is used when 5 or more are affected.
- Is the axial skeleton (thoracic spine, lumbar spine, sacroiliac joints or anterior costochondral joints) affected?

Determining whether the condition is articular or nonarticular, inflammatory or noninflammatory, and acute or

chronic and assessing the pattern of the joints involved will provide a detailed description of the musculoskeletal problem that can stand alone as the diagnosis or may facilitate a more specific one. For example, the patient may have a chronic, inflammatory, symmetrical, small-

joint polyarthritis. The most common rheumatic diseases fitting this description, and the most likely specific diagnoses, are rheumatoid arthritis, psoriatic arthritis or 1 of the connective tissue disorders. If the patient has a chronic, inflammatory, asymmetrical, large-joint polyarthritis with inflammatory spine involvement, the diagnosis is most probably 1 of the seronegative spondyloarthropathies, whereas a chronic, inflammatory, asymmetrical, small-joint oligoarthritis strongly suggests a diagnosis of psoriatic arthritis.

The pattern and type of joints involved will also help the physician arrive at a specific rheumatologic diagnosis. Osteoarthritis commonly affects the proximal and distal interphalangeal joints of the fingers and the first carpometacarpal joints in the hands but rarely involves the metacar-

pophalangeal joints, wrists, elbows or ankles. Chronic, inflammatory polyarthritis involving the metacarpophalangeal joints in the hands, wrists, elbows or ankles is typical of rheumatoid arthritis, psoriatic arthritis or 1 of the connective tissue disorders.

Are there any associated signs or symptoms?

In arriving at a specific rheumatologic diagnosis, the physician should also proceed through a review of systems to determine whether there are any extra-articular symptoms or signs associated with the joint problem. A collection of certain features (a syndrome) in association with the

Key points

- Diagnosis of rheumatic disease is based primarily on the patient’s history and physical examination.
- Once the patient has identified the exact site of the pain the physician should determine if the conditions is:
 - Articular or nonarticular. To determine this the active and passive ranges of motion of the affected joints should be evaluated.
 - Inflammatory or noninflammatory. This will form the the basis of treatment.
 - Acute or chronic.
- The pattern of joint involvement will help the physician arrive at a specific rheumatologic diagnosis.
- The patient should also be examined for extra-articular features that are often associated with the common rheumatologic diseases; these may lead the physician to a more specific diagnosis.

Table 2: Differentiating inflammatory from noninflammatory conditions

Sign	Inflammatory articular problems (e.g., arthritis)	Noninflammatory articular problems (e.g., osteoarthritis)	Inflammatory nonarticular problems (e.g., bursitis, tendinitis)
Warmth	Yes, diffusely over the joint	No	Sometimes, but localized over the structure (i.e., tendon or bursa)
Swelling	Yes, usually; the joint is diffusely swollen (effusion)	No joint effusion, but bony enlargement may be present	Yes, but swelling is localized over the particular structure
Redness	Rarely; if present the joint is diffusely red	No	Rarely, but again, localized
Tenderness	Yes, over the joint line	Yes, over the joint line	Yes, over the particular structure

appropriate musculoskeletal description, will confirm the diagnosis of the rheumatic condition. Table 3 lists the main extra-articular features associated with the most common rheumatologic diseases. In isolation, many of these extra-articular manifestations do not indicate a specific diagnosis; it is when several of these features are present together that a more specific syndrome can be recognized. The physician must specifically ask for this information because patients do not usually volunteer it.

Dry eyes or mouth

Many patients complain of dry eyes or mouth. True xero-ophthalmia may be present when the patient can no longer wear contact lenses because of dry eyes, continues to have dry eyes when they stop wearing contact lenses, wakes through the night or in the morning with dry eyes and has sought the use of artificial tears. The patient should be sent to an ophthalmologist for a Schirmer's test or Rose-Bengal test if it is necessary to document dry eyes.⁶ True xerostomia (dry mouth) may be present if the patient is no longer able to eat or swallow dry foods without fluids. Often the patient will need to carry water or keep water at the bedside at night. Physical examination of the mouth is usually normal until xerostomia is advanced.

Hair loss

Hair loss is probably significant if the pillowcase is covered with hair in the morning. To determine the extent of the problem patients can be asked to count the number of hairs lost per day; more than 200 is considered significant hair loss.

Table 3: Extra-articular features of common rheumatic disorders

Rheumatic disorder	Common extra-articular features
Rheumatoid arthritis	Dry eyes, scleritis, dry mouth, nail-fold infarcts, rheumatoid nodules, pleuritis
Connective tissue disorders*	Hair loss, oral or nasal ulcerations, dry eyes, dry mouth, malar erythema, photosensitivity, pleuritis, pericarditis, Raynaud's phenomenon, sclerodactyly, esophageal dysmotility
Seronegative spondyloarthropathies	Psoriasis or nail pits (seen in psoriatic arthritis), inflammatory bowel disease (seen in inflammatory bowel disease-associated spondyloarthritis), conjunctivitis and urethritis or cervicitis (seen in reactive spondyloarthritis or Reiter's syndrome)
Gout	Tophi
Fibromyalgia	Irritable bowel syndrome, irritable bladder syndrome, depression, vague paresthesias

*Includes systemic lupus erythematosus, Sjögren's syndrome, systemic sclerosis and variants, mixed connective tissue disease, dermatomyositis and polymyositis.

Oral and nasal ulcerations

Patients should be questioned about and examined for oral and nasal ulcerations. A physical examination is required because, although some ulcers can be very painful, others may be painless. If the patient has been experiencing intermittent ulcerations throughout life and there has been no change in frequency or severity, the ulcerations are probably not significant. However, if the ulcerations are of recent onset, occur in outbreaks or clusters in the absence of any precipitant and occur frequently (i.e., more than once monthly), they are probably significant and could be associated with a rheumatic disease.⁶

Malar erythema

Patients with systemic lupus erythematosus may experience malar erythema that is flat or raised but not pustular; malar erythema with pustules is typical of the common rash, acne rosacea. A systemic lupus erythematosus malar rash usually involves the cheeks and the bridge of the nose but spares the nasolabial folds, while acne rosacea involves the nasolabial folds. Both are often photosensitive.⁷

Photosensitive rash

A significant photosensitive rash is usually an erythematous, maculopapular eruption that might ulcerate or scale (but is not vesicular); it occurs quickly on sun-exposed areas (within 30 min of sun exposure), often takes several days to subside once out of the sun and is often reported to be pruritic but is tender when scratched.⁷

Raynaud's phenomenon

Raynaud's phenomenon occurs in about 8% of women. It is probably significant if the onset is recent (within the past 2 years), it involves 1 or several digits at a time but not all digits at the same time, and it occurs on exposure to either mildly cold temperatures or at any time unrelated to cold exposure.⁸ Raynaud's phenomenon is pathologic if there are associated digital ulcerations, digital pitting scars or digital tuft loss. Although classic Raynaud's phenomenon is triphasic (white, blue and hyperemic colour phases), for diagnosis the patient need only describe the white phase.

In addition to these symptoms and signs, which are common in the rheumatic diseases but are not specific for the rheumatic diseases, a few findings are characteristic (pathognomic) of rheumatic disease. Nail-fold infarctions are tiny, painful black dots in the periungual areas and indicate the presence of small-vessel vasculitis. They are particularly common in rheumatoid arthritis but might also be seen in systemic lupus erythematosus or in 1 of the vasculitic disorders. Rheumatoid nodules are nontender, non-erythematous, mobile, subcutaneous nodules that usually occur around joints or on pressure areas; they are also vas-

culitic lesions and occur commonly in severe rheumatoid arthritis, but may also be seen in the connective tissue diseases, especially systemic lupus erythematosus. Gouty tophi, which are pathognomic for gout, can resemble rheumatoid nodules (except gouty tophi can occur on the helix of the ears). Sclerodactyly (i.e., thickening of the skin distal to the metacarpophalangeal joints of the hands or the metatarsalphalangeal joints of the feet so that the skin cannot be pinched by the examiner) usually indicates the presence of connective tissue disease, specifically, systemic sclerosis, CREST (calcinosis, Raynaud's phenomenon, esophageal dysmotility, sclerodactyly, telangiectasias) syndrome or mixed connective tissue disease but may also occur rarely after exposure to certain antineoplastic agents or in hematologic malignancies.

Diagnosing our patients' problems

Returning to our patients, the 29-year-old woman has recurrent (suggesting chronicity), inflammatory, symmetrical small-joint polyarthritis in the absence of any extra-articular features except fatigue. The onset was postpartum. This clinical picture is most consistent with a diagnosis of rheumatoid arthritis.

The 69-year-old woman has chronic, noninflammatory joint pains in the pattern of joints typically seen with osteoarthritis, without extra-articular features. The diagnosis is primary generalized osteoarthritis.

The 40-year-old man has chronic, inflammatory, asymmetric, large-joint oligoarthritis with inflammatory spine involvement compatible with a diagnosis of ankylosing spondylitis.

The 50-year-old school teacher has chronic, generalized,

noninflammatory, nonarticular musculoskeletal complaints typical of fibromyalgia syndrome. In addition, she has described irritable bowel syndrome, which is common in patients with fibromyalgia.

In summary, musculoskeletal problems are the second-most common complaint for which medical attention is sought at the primary care level. By following the 5 basic steps described here, a physician can arrive at a rheumatologic diagnosis that is precise enough to serve as the basis for further investigations and treatment.

Competing interests: None declared.

References

1. Glazier RH, Dalby DM, Badley EM, Hawker GA, Bell MJ, Buchbinder R. Determinants of physician confidence in the primary care management of musculoskeletal disorders. *J Rheumatol* 1996;23:351-6.
2. Glazier RH, Dalby DM, Badley EM, Hawker GA, Bell MJ, Buchbinder R, et al. Management of the early and late presentations of rheumatoid arthritis: a survey of Ontario primary care physicians. *CMAJ* 1996;155(6):679-87. Abstract available: www.cma.ca/cmaj/vol-155/issue-6/0679.htm
3. Glazier RH, Dalby DM, Badley EM, Hawker GA, Bell MJ, Buchbinder R, et al. Management of common musculoskeletal problems: a survey of Ontario primary care physicians. *CMAJ* 1998;158(8):1037-40. Abstract available: www.cma.ca/cmaj/vol-158/issue-8/1037.htm
4. Hoppenfeld S. *Physical examination of the spine and extremities*. London: Appleton-Century-Crofts; 1976.
5. Cyriax JH, Cyriax PJ. *Cyriax's illustrated manual of orthopaedic medicine*. 2nd ed. Oxford: Butterworth Heinemann; 1993.
6. Klippel JH, Dieppe PA, editors. *Rheumatology*. 2nd ed. Philadelphia: Mosby; 1998.
7. Wallace DJ, Hahn BH, editors. *Dubois' lupus erythematosus*. 5th ed. Baltimore: Williams and Wilkins; 1997.
8. Kelley WN, Harris ED Jr, Ruddy S, Sledge CB, editors. *Textbook of rheumatology*. 5th ed. Philadelphia: WB Saunders; 1997.

Reprint requests to: Dr. Stephanie Ensworth, Clinical Assistant Professor of Medicine, University of British Columbia, Mary Pack Arthritis Centre, 895 W 10th Ave., Vancouver BC V5Z 1L7; fax 604 871-4556; s_ensworth@ibm.net