

# Anaphylactoid reactions and angioedema during alteplase treatment of acute ischemic stroke

Michael D. Hill, Philip A. Barber, Jennifer Takahashi,  
Andrew M. Demchuk, Thomas E. Feasby, Alastair M. Buchan

## Abstract

AMONG 105 PATIENTS GIVEN RECOMBINANT tissue plasminogen activator (rt-PA, alteplase) intravenously for acute stroke, 2 (1.9%) had lingual angioedema, which progressed to a fatal anaphylactoid reaction in 1. The authors review the 2 cases and possible mechanisms responsible. They warn that patients who are taking an angiotensin-converting-enzyme inhibitor may be at increased risk for angioedema with concomitant alteplase therapy.

A major concern of physicians who treat acute ischemic stroke with alteplase, a recombinant tissue plasminogen activator (rt-PA, ) is the risk of intracerebral hemorrhage. However, other adverse reactions, including anaphylaxis and angioedema, can also occur. Hypersensitivity to alteplase is uncommon and has been estimated to occur in less than 0.02% of patients who receive it for the treatment of acute myocardial infarction.<sup>1</sup> Anaphylactoid reactions to alteplase in patients treated for acute ischemic stroke may be more common, however. Of 105 consecutive patients we treated with intravenous alteplase for acute ischemic stroke, 2 had anaphylactoid reactions. We describe their cases here.

## Case reports

### Case 1

A 74-year-old woman with known coronary artery disease, adult onset type 2 diabetes mellitus, hypertension and congestive heart failure collapsed. She was taking ASA, losartan, furosemide, diltiazem, digoxin, atorvastatin, acarbose and glyburide and was wearing a nitroglycerine skin patch. She was in atrial fibrillation but was not taking anticoagulants. On arrival at the hospital she was awake, globally aphasic and had a right homonymous hemianopia. Her eyes were tonically deviated to the left with a dense right hemiplegia. She had no sensation of painful stimuli on the right side. Her plantar response was extensor on the right. Her National Institutes of Health Stroke Scale (NIHSS) score was 24 (a score over 15 indicates severe stroke). A CT brain scan performed 90 minutes following stroke onset showed a hyperdense left middle cerebral artery sign and early signs of infarction in the left lentiform nucleus and insular ribbon. Her platelet count, international normalized ratio (INR) and activated partial thromboplastin time were normal, and her blood pressure was 180/70 mm Hg. The patient met the criteria for intravenous alteplase treatment of acute ischemic stroke and was given 0.9 mg/kg alteplase — a 10% bolus initially and the remaining drug infused over 60 minutes.

The patient began to improve within 30 minutes of treatment initiation, with some fluent speech and spontaneous movement in her right arm and leg. However, 15 minutes later she was noted to be in some discomfort and was attempting to scratch her left arm. The first signs of an urticarial rash were noted, and it subsequently spread from her legs to large areas of her abdomen and chest. The alteplase infusion was stopped; the patient had received a total of 38 mg of the drug.

## Research

## Recherche

From the Department  
of Clinical Neurosciences,  
University of Calgary,  
Calgary, Alta.

*This article has been peer reviewed.*

CMAJ 2000;162(9):1281-4

[Return to May 2, 2000  
Table of Contents](#)

Extensive bilateral swelling of her tongue and periorbital region developed, and her blood pressure dropped to 90/40 mm Hg. Hydrocortisone (100 mg), diphenhydramine (50 mg), ranitidine (50 mg) and crystalloid were administered intravenously. Stridor developed, and there was massive swelling of the epiglottis, uvula and tongue; a traumatic intubation resulted in some oropharyngeal hemorrhage. It was unclear whether her oropharyngeal swelling was complicated by the hemorrhage in addition to angioedema. Fresh frozen plasma (8 units), cryoprecipitate (20 units) and red blood cells (4 units) were given for possible retropharyngeal hematoma. A follow-up CT scan of the neck showed swelling but no hematoma. The patient suffered a small midline brainstem hemorrhage and petechial hemorrhage into the area of infarction (left middle cerebral artery territory). She was admitted to the intensive care unit and was making moderate neurological improvement. However, 14 days after stroke onset the patient experienced ventricular arrhythmia and, despite attempts to resuscitate, died. An autopsy was not performed.

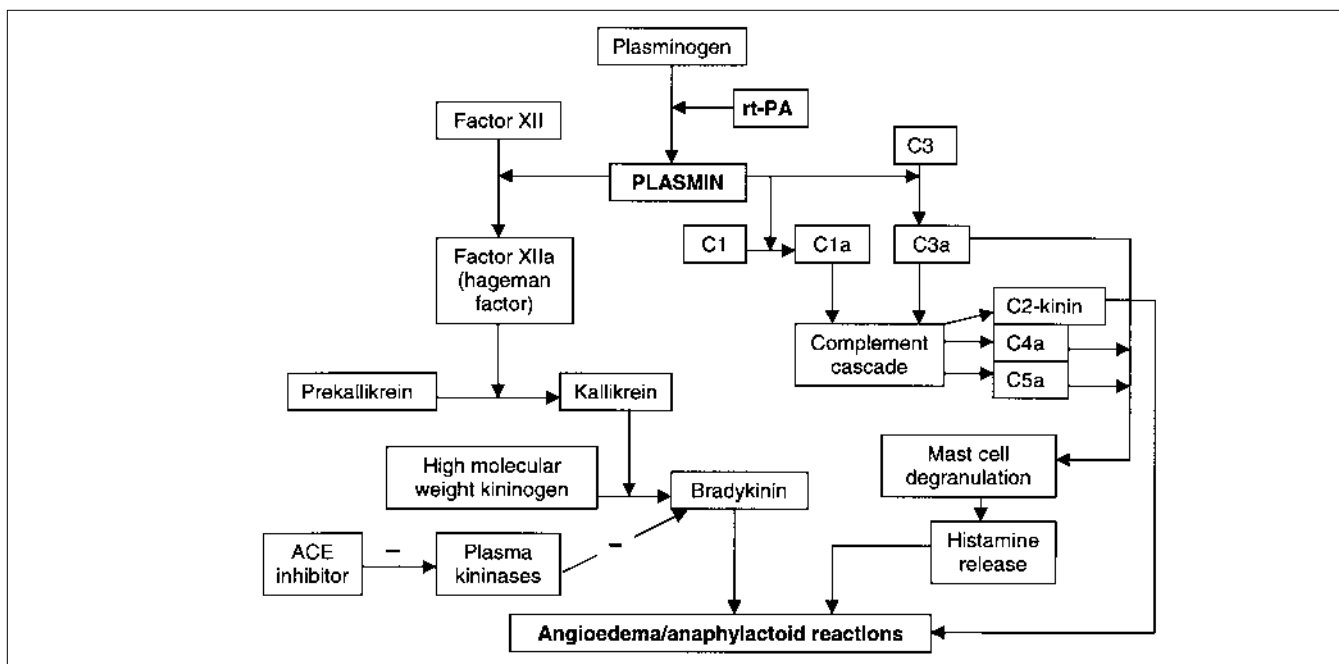
On the day the patient was admitted to the hospital her serum glucose level was 29 mmol/L, perhaps partly explaining her intraparenchymal cerebral hemorrhage.<sup>2</sup> Levels of complement C3 and C4 were normal the day after her stroke. She was not taking an angiotensin-converting-enzyme (ACE) inhibitor. Additional history obtained from the family revealed that the woman had experienced 8 episodes of angioedema in the previous 14 years — 1 while

she was taking a  $\beta$ -blocker and another while she was taking an ACE inhibitor.

## Case 2

A 76-year-old woman with chronic atrial fibrillation (treated with digoxin but not anticoagulants or ASA), coronary artery disease, a previous transient ischemic attack and hypertension presented to the hospital with sudden onset of right-gaze preference, left hemiplegia and left hemispatial neglect. On arrival she was awake and oriented but drowsy and easily rousable. She had a left hemianopia and left visual hemineglect. Sensation on her left side was altered but not absent. A brain CT scan revealed a hyperdense left middle cerebral artery sign and early signs of infarction in the lentiform nucleus and anterior middle cerebral artery territory. Her NIHSS score was 18, blood pressure 165/96 mm Hg, serum glucose 8.1 mmol/L, INR 1.0 and platelet count  $154 \times 10^9/L$ . She had slight microcytic anemia, with a hemoglobin concentration of 105 g/L, but an otherwise normal blood smear. She was taking an ACE inhibitor. Intravenous alteplase (0.9 mg/kg, 10% initial bolus dose and the remaining drug infused over 60 minutes) was initiated 110 minutes after stroke onset.

Thirty minutes after the alteplase infusion was finished, the patient had unilateral swelling of her tongue and lips on the left side, but she had no rash or hypotension. She was treated with methylprednisolone (80 mg), diphenhy-



**Fig. 1:** In addition to activating fibrinolysis, plasmin may activate the complement cascade by directly cleaving C1 and C3. The release of each of the anaphylotoxins, C3a, C4a, C5a and C2-kinin, contributes to angioedema. Plasmin may also directly activate the kinin pathway, leading to the production of bradykinin, a potent vasodilator. Kininases may be inhibited by angiotensin-converting-enzyme (ACE) inhibitors, providing a putative mechanism for the observed association between angioedema after alteplase treatment and ACE inhibitors. – indicates inhibition.

dramine (50 mg) and ranitidine (25 mg), and her symptoms resolved over several hours.

## Comments

Allergic reactions to thrombolytic agents can occur but are most commonly seen with streptokinase administration; anaphylaxis is uncommon.<sup>3,4</sup> Angioedema has been reported in association with alteplase treatment of myocardial ischemia<sup>5,6</sup> and deep vein thrombosis,<sup>7,8</sup> but very rarely in association with alteplase treatment of acute ischemic stroke.<sup>9-12</sup> Anaphylactoid reactions or angioedema have been reported to occur in less than 0.02% of patients treated with alteplase for acute myocardial infarction. However, over a 3-year period we observed these adverse reactions in 2 (1.9% [95% confidence interval 0.2%–6.7%]) of the 105 patients given alteplase for acute ischemic stroke. Fayad and colleagues<sup>11</sup> reported similar reactions in 4 (1.5%) of 260 patients.

Anaphylaxis and angioedema during alteplase infusion are likely caused by the activation of the complement and kinin cascades.<sup>13</sup> Although anti-alteplase antibodies have been reported, alteplase is an endogenous protein and thus has low antigenicity in humans.<sup>10,14</sup> IgG or IgM antibodies have been found in serum only days to weeks after alteplase treatment.<sup>15-17</sup> However, IgE antibodies to alteplase were detected in one case of anaphylaxis without angioedema.<sup>10</sup> Activation of the complement system is likely direct, rather than through the binding of complement C1 to antigen-antibody complexes containing IgG or IgM.

Plasminogen activator is a serine protease that cleaves plasminogen to plasmin (Fig. 1). Plasmin cleaves thrombus-bound fibrin, which results in the fibrinolytic effect, and can also activate the complement cascade and kinin pathway. Bradykinin is a potent vasodilator with a short half-life due to the action of plasma kininases. Plasma kininases may be inhibited by ACE inhibitors, but angioedema secondary to ACE inhibitors in some patients may be associated with a genetic defect in bradykinin metabolism.<sup>19</sup>

The activation of complement C3 results in an amplification of the complement cascade via the alternate pathway; C3a, the cleavage product of C3, is a potent anaphylotoxin that activates mast-cell degranulation and histamine release. C4a and C5a also activate mast-cell degranulation. Experimental evidence suggests that anaphylaxis results in an upregulation of endogenous t-PA levels,<sup>20,21</sup> and C3a, C4a and C5a show a marked increase after alteplase administration.<sup>13</sup> Activation of angioedema in this fashion may not necessarily lead to complement consumption and low C3 and C4 levels. Plasmin may also directly activate C1 in the classic pathway with the release of C2-kinin, another potent vasodilator thought to be responsible for angioedema in both hereditary and acquired C1 esterase inhibitor deficiency.<sup>19</sup>

Each vial of alteplase used in North America contains 100 mg of alteplase, 3.5 g of L-arginine, 1 g of phosphoric

acid and 8 mg of polysorbate-80. It contains no preservatives and is reconstituted with sterile water. The concentration of L-arginine may be enough to stimulate endothelial nitric oxide synthase (eNOS); both the kinins and the eNOS may have contributed to the adverse reactions and hypotension we documented. Using nitroarginine as the carrier might reduce risk and prevent nitric-oxide-induced neurotoxicity.<sup>22</sup>

In hindsight, our first patient may have had an undiagnosed hereditary or acquired C1 esterase inhibitor deficiency. C1 esterase inhibitor is a member of the  $\alpha$ 2-macroglobulin family and has antiplasmin activity. A deficiency in this patient may have resulted in an overwhelming activation of the complement cascade and severe oropharyngeal angioedema. The second patient's angioedema was milder, and we suspect that ACE inhibition made her susceptible.

An intriguing aspect of these and other cases is that the angioedema of the tongue or lips began unilaterally and if severe enough progressed to involve the entire tongue and oropharynx. Several others<sup>23-25</sup> have investigated the role of the insular cortex in sympathetic and parasympathetic control. We speculate that infarction of the contralateral insular cortex, leading to autonomic dysregulation and changes in vasomotor tone on the hemiparetic side of the body, interacted with the angioedema cascade and resulted in the apparent initial localization of the angioedema on the symptomatic side.

Physicians treating acute ischemic stroke with alteplase should be aware of this infrequent complication. We routinely inspect the tongue and oropharynx in patients 30–45 minutes after the start of an alteplase infusion and pay particular attention to patients taking ACE inhibitors. A history of ACE inhibitor use should always be obtained before treatment with alteplase is initiated.

Our treatment with antihistamines and corticosteroids has been empirical and is based on the treatment of angioedema associated with hereditary or acquired deficiency in C1 esterase inhibitor. Infusion of C1 esterase inhibitor has been reported in the treatment of acute myocardial ischemia<sup>26</sup> for its possible myocardial-protective effect, and an infusion of C1 esterase inhibitor may be an effective therapy in this situation as well. We avoided the use of epinephrine because of the possibility of increasing the risk of intracerebral hemorrhage with a sudden rise in blood pressure.

## Addendum

Since the submission of this article we have observed 2 other cases of hemilingsual angioedema of the tongue (each ipsilateral to the hemiplegia) in patients treated with alteplase for acute ischemic stroke. Both cases were mild and resulted in symptoms of dysphagia in the first patient and no symptoms in the second patient. Both patients were taking an ACE inhibitor and both were treated with ranitidine (50 mg) and diphenhydramine (50 mg) intravenously; the angioedema was resolved in both cases within 60 minutes.

Drs. Hill and Buchan received grants from the Medical Research Council of Canada, the Heart and Stroke Foundation of Canada and the Alberta Heritage Foundation for Medical Research. Dr. Feasby is funded by a grant from the Heart and Stroke Foundation of Canada.

Competing interests: None declared for Drs. Takahashi, Feasby and Demchuk. Drs. Hill and Buchan have received speaker fees from Hoffman-La Roche Canada Limited, and Dr. Barber has received travel assistance from Knoll Pharmaceutical Company.

## References

- Canadian Pharmacists Association. *Compendium of pharmaceuticals and specialties*. 34th ed. Ottawa: The Association; 1999. p. 31.
- Demchuk AM, Morgenstern LB, Krieger DW, Chi TL, Hu W, Wein TH, et al. Serum glucose level and diabetes predict tissue plasminogen activator-related intracerebral hemorrhage in acute ischemic stroke. *Stroke* 1999;30:34-9.
- Tsang TS, Califf RM, Stebbins AL, Lee KL, Cho S, Ross AM, et al. Incidence and impact of an outcome of streptokinase allergy in the GUSTO-1 trial. Global Utilization of Streptokinase and t-PA in Occluded Coronary Arteries. *Am J Cardiol* 1997;79:1232-5.
- White HD, Cross DB, Williams BF, Norris RM. Safety and efficacy of repeat thrombolytic treatment after acute myocardial infarction. *Br Heart J* 1990;64:177-81.
- Purvis JA, Booth NA, Wilson CM, Aggi JAA, McClusky DR. Anaphylactoid reaction after injection of alteplase. *Lancet* 1993;341:966-7.
- Massell D, Gill JB, Cairns JA. Anaphylactoid reaction during infusion of recombinant tissue-type plasminogen activator for acute myocardial infarction. *Can J Cardiol* 1991;7:298-302.
- Francis CW, Brenner B, Leddy JP, Marder VJ. Angioedema during therapy with recombinant tissue plasminogen activator. *Br J Haematol* 1991;77:562-3.
- Marder VJ, Brenner B, Totterman S, Francis CW, Rubin R, Rao AK, et al. Comparison of dosage schedules of rt-PA in the treatment of proximal deep vein thrombosis. *J Lab Clin Med* 1992;119:485-95.
- Pancioli A, Brott T, Donaldson V, Miller R. Asymmetric angioneurotic oedema associated with thrombolysis for acute stroke. *Ann Emerg Med* 1997;30:227-9.
- Rudolf J, Grond M, Prince WS, Schmulling S, Heiss WD. Evidence of anaphylaxis following alteplase infusion. *Stroke* 1999;30:1142-3.
- Fayad PB, Albers GW, Frey JL, Raps EC. Orolingual angioedema complicating rt-PA therapy for acute ischemic stroke [abstract]. *Stroke* 1999;30:242.
- Felberg RA, Wein TH, Demchuk AM, Hickenbottom SL, Malkoff M, Morgenstern LB, et al. Oropharyngeal angioedema: a clinically important complication of intravenous recombinant tissue plasminogen activator [abstract]. *124th Annual Meeting of the American Neurological Association*; 1999 Oct 9-13; Seattle.
- Bennett WR, Yawn DH, Migliore PJ, Young JB, Pratt CM, Raizner AE, et al. Activation of the complement system by recombinant tissue plasminogen activator. *J Am Coll Cardiol* 1987;10:627-32.
- Reed BR, Chen AB, Tanswell P, Prince WS, Wert RM Jr, Glaesle-Schwarz L, et al. Low incidence of antibodies to recombinant human tissue-type plasminogen activator in treated patients. *Thromb Haemost* 1990;64:276-80.
- Topol EJ, Morris DC, Smalling RW, Schumacher RR, Taylor CR, Nishikawa A, et al. A multi-centre randomized placebo controlled trial of a new form of intravenous recombinant tissue-type plasminogen activator in acute myocardial infarction. *J Am Coll Cardiol* 1987;9:1205-13.
- Cugno M, Cicardi M, Colucci M, Bisiani G, Merlini PA, Spinola A, et al. Non-neutralizing antibodies to tissue-type plasminogen activator in the serum of acute myocardial infarction patients treated with the recombinant protein. *Thromb Haemost* 1996;76:234-8.
- Reed BR, Chen AB, Tanswell P, Prince WS, Wert RM, Glaesle-Schwarz L, et al. Low incidence of antibodies to recombinant human tissue-type plasminogen activator in treated patients. *Thromb Haemost* 1990;64:276-80.
- Blais C Jr, Rouleau JL, Brown NJ, Lepage Y, Spence D, Munoz C, et al. Serum metabolism of bradykinin and des-Arg9-bradykinin in patients with angiotensin-converting enzyme inhibitor-associated angioedema. *Immunopharmacology* 1999;43:293-302.
- Markovic SN, Inwards DJ, Frigas EA, Phyllyk RP. Acquired C1 esterase inhibitor deficiency. *Ann Intern Med* 2000;132:144-50.
- Van der Linden PWG, Hack E, Struyvenberg A, Roem D, Brouwer MC, de Boer JP, et al. Controlled insect-sting challenge in 55 patients: correlation between activation of plasminogen and the development of anaphylactic shock. *Blood* 1993;82:1740-8.

- Shimaya K, Sumi H, Maruyama M, Mihara H. A rapid and strong increase of plasminogen activator induced by experimental anaphylaxis in rabbits. *Enzyme* 1992;46:204-12.
- Buchan AM, Gertler SZ, Huang ZG, Li H, Chaundy KE, Xue D. Failure to prevent selective CA1 neuronal death and reduce cortical infarction following cerebral ischemia with inhibition of nitric oxide synthase. *Neuroscience* 1994;61:1-11.
- Zamrini EY, Meador KJ, Loring DW, Nichols FT, Lee GP, Figueroa RE, et al. Unilateral cerebral inactivation produces differential left/right heart rate responses. *Neurology* 1990;40:1408-11.
- Oppenheimer SM, Gelb A, Girvin JP, Hachinski VC. Cardiovascular effects of human insular cortex stimulation. *Neurology* 1992;42:1727-32.
- Yoon BW, Morillo CA, Cechetto DR, Hachinski V. Cerebral hemispheric lateralization in cardiac autonomic control. *Arch Neurol* 1997;54:741-4.
- Bauernschmitt R, Bohrer H, Hagl S. Rescue therapy with C1-esterase inhibitor concentrate after emergency coronary surgery for failed PTCA. *Intensive Care Med* 1998;24:635-8.

**Reprint requests to:** Dr. Michael D. Hill, Department of Clinical Neurosciences, University of Calgary, MRG 005, Foothills Hospital, 1403 29th St. NW, Calgary AB T2N 2T9; fax 403 670-1602; michael.hill@crrha-health.ab.ca

## 2000 Physician Manager Institute

**For the leadership and management skills necessary to function effectively**

Approved for RCPSC, CFPC and AAFP study credits

### PMI-1 / PMI-2

June 4-6 / June 7-9, 2000

Sept. 24-26 / Sept. 27-29, 2000

Nov. 5-7 / Nov. 8-10, 2000

Château Laurier, Ottawa

The Queen Elizabeth, Montréal

Sutton Place Hotel, Vancouver

### PMI Refresher

Oct. 20-22, 2000

Sutton Place Hotel, Vancouver

### In-house PMI

A practical, cost-effective and focused training opportunity held on site for leaders and managers

For information:

tel 800 663-7336 or 613 731-8610

x2319 (PMI) or x2261 (In-house PMI)

michah@cma.ca

www.cma.ca/prodev/pmi

ASSOCIATION  
MÉDICALE  
CANADIENNE



CANADIAN  
MEDICAL  
ASSOCIATION



Canadian College of Health Service Executives  
Collège canadien des directeurs de services de santé