

CLINICAL IMAGES

Bleomycin-induced flagellate dermatitis

Diana Yu Diao BSc, John Goodall MD

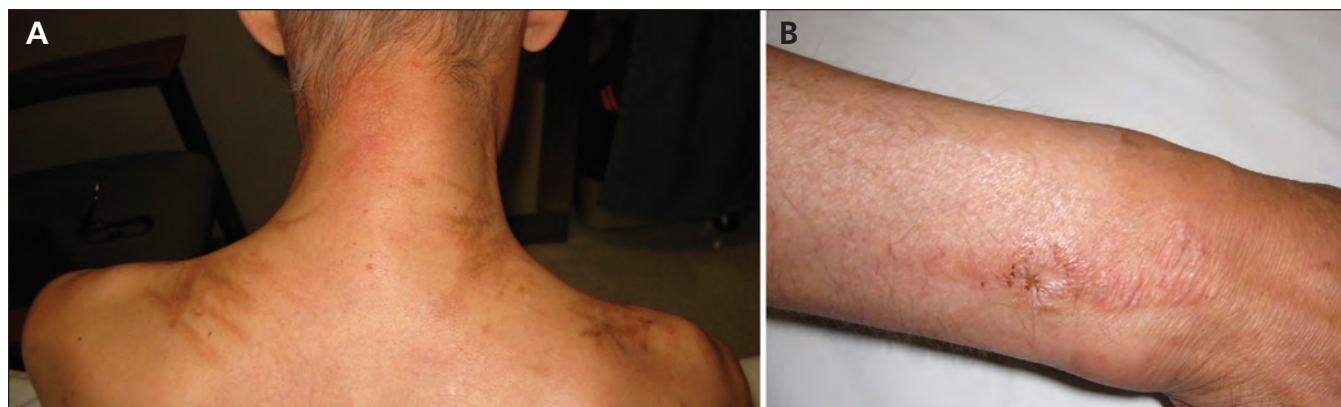


Figure 1: (A) Crisscrossing flagellate hyperpigmentation over the shoulders and neck of a 48-year-old man receiving bleomycin for Hodgkin's lymphoma. (B) The patient also presented with a linear, urticarial, eczematous lesion on his wrist.

Competing interests: None declared.

This article has been peer reviewed.

Affiliations: From the Faculty of Medicine (Diao) University of British Columbia, Vancouver, BC; and the Ottawa Hospital (Goodall), University of Ottawa, Ottawa, Ont.

Correspondence to: Diana Yu Diao, ddiao@interchange.ubc.ca

CMAJ 2012, DOI:10.1503/cmaj.111889

A 48-year-old white man presented with a 4-week history of itchy lesions on the skin of his upper back and shoulders. The patient's medical history included ulcerative colitis and a seizure disorder. In addition, Hodgkin's lymphoma had been diagnosed three months earlier, for which the patient was receiving doxorubicin, bleomycin, vinblastine and dacarbazine chemotherapy. The lesions appeared during the patient's fourth cycle of chemotherapy, after having received 64 units of bleomycin in total.

On examination, the patient had crisscrossing flagellate hyperpigmentation over his shoulders and neck (Figure 1A), and a red, raised lesion was developing on the back of his right wrist (Figure 1B). The patient reported linear reddish marks, similar to the one on his wrist, having preceded some of the hyperpigmented streaks. Histopathology of both lesions showed superficial perivascular dermatitis with eosinophils and minimal changes at the vacuolar interface, likely representing the same disease process, with features suggesting a drug-induced reaction.

Bleomycin is a glycopeptide antineoplastic antibiotic agent used in chemotherapy for Hodgkin's lymphoma, squamous cell carcinoma and testicular cancer. The drug is metabolized by bleomycin hydrolase, but it has been shown to have adverse effects in tissues with relatively low

levels of this enzyme, such as the lungs and skin.^{1,2} Minor trauma to the skin, such as pressure over bony prominences and scratching, is thought to increase blood flow and cause local accumulation of bleomycin.³ Flagellate dermatitis and subsequent hyperpigmentation in the skin is fairly common among patients receiving bleomycin, with reported incidence between 8% and 22%.³ Flagellate dermatitis is not typically associated with the other medications our patient was receiving.

Various topical and systemic therapies have been tried, but treatment mostly involves management of symptoms to limit trauma to the skin. The lesions typically resolve within six months after the withdrawal of bleomycin.⁴ After treatment with fluocinonide ointment and withdrawal of bleomycin, signs of active inflammation resolved, and our patient's hyperpigmentation was lightened at a follow-up appointment five weeks later.

References

1. Lazo JS, Humphreys CJ. Lack of metabolism as the biochemical basis of bleomycin-induced pulmonary toxicity. *Proc Natl Acad Sci U S A* 1983;80:3064-8.
2. Dantzig PI. Immunosuppressive and cytotoxic drugs in dermatology. *Arch Dermatol* 1974;110:393-406.
3. Ziemer M, Goetze S, Juhasz K, et al. Flagellate dermatitis as a bleomycin-specific adverse effect of cytostatic therapy. *Am J Clin Dermatol* 2011;12:68-76.
4. Mowad CM, Nguyen TV, Elenitsas R, et al. Bleomycin-induced flagellate dermatitis: a clinical and histopathological review. *Br J Dermatol* 1994;131:700-2.