

CLINICAL IMAGES

Amiodarone-induced pulmonary toxicity

Bartosz Hudzik MD, Lech Polonski MD PhD

A 74-year-old man, a current smoker, presented with shortness of breath and a dry cough. He had a history of ventricular tachyarrhythmia treated with amiodarone (200 mg/d for 6 years), a previous myocardial infarction and coronary artery bypass surgery.

On examination, bilateral crackles could be heard on inspiration. Clubbing was absent. Radiography of the patient's chest showed diffuse interstitial and alveolar opacities, and echocardiography showed mild dysfunction of the left ventricle with an ejection fraction of 48%. His arterial blood gases were normal, but pulmonary function

tests showed restriction with a reduced carbon monoxide–diffusing capacity (45% of predicted). High-resolution computed tomography showed signs consistent with amiodarone-induced interstitial pulmonary fibrosis (Figure 1). Amiodarone was stopped, and an alternate antiarrhythmic agent was used. The patient's symptoms improved.

Amiodarone is associated with a wide range of adverse effects, including pulmonary toxicity. With long-term use, the prevalence of such toxicity varies between 5% and 15%.¹ The spectrum of disease ranges from mild chronic or subacute lung disease to rapidly progressing acute airway and lung disease, including acute respiratory distress syndrome with high mortality.² Risk factors include a high cumulative dose of the drug (≥ 100 g), a high daily dose (≥ 400 mg), long-lasting therapy (≥ 2 mo), pre-existing lung disease and older age.¹ Lower doses (≤ 200 mg/d) have also been associated with serious pulmonary toxicity.^{1,3}

Symptoms can include progressive dyspnea, dry cough, malaise and pleuritic chest pain. Bilateral crackles may be heard on examination. Radiographic features can include interstitial or alveolar (ground-glass) shadows that may be localized or diffuse, and traction bronchiectases with a honeycombing pattern (Appendix 1, available at www.cmaj.ca/lookup/suppl/doi:10.1503/cmaj.111763/-/DC1).¹⁻³ Pulmonary function tests may show reduced carbon monoxide–diffusing capacity. Stopping amiodarone therapy is the treatment of choice. Despite a lack of controlled studies, experts suggest that corticosteroids may help patients with acute disease, hypoxemia and substantial involvement seen on imaging.¹⁻³ The prognosis is usually good in cases of chronic or subacute disease. Because pulmonary fibrosis may develop, a lung biopsy is suggested if symptoms do not improve within 1 or 2 months of drug withdrawal.¹

Competing interests: None declared.

This article has been peer reviewed.

Affiliation: Third Department of Cardiology, Silesian Center for Heart Disease, Medical University of Silesia, Zabrze, Poland.

Correspondence to: Bartosz Hudzik, bartekh@mp.pl

CMAJ 2012, DOI:10.1503/cmaj.111763

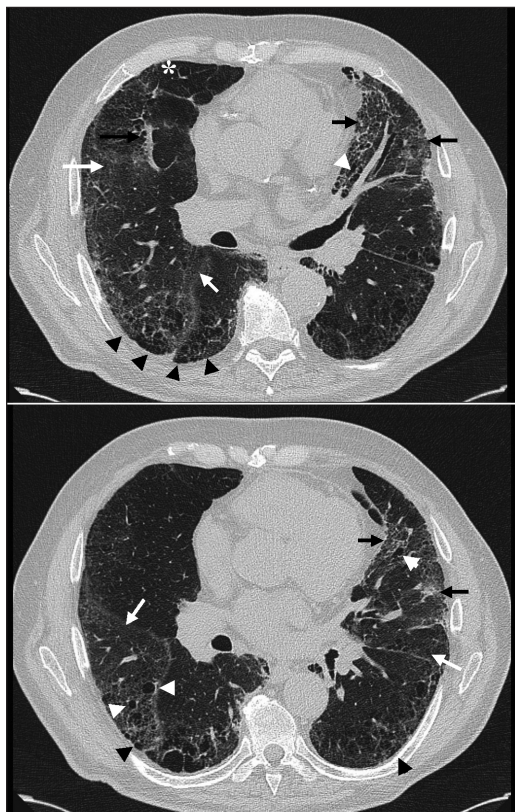


Figure 1: High-resolution computed tomography images of the chest of a 74-year-old man with dyspnea and cough. Bilateral, ground-glass opacities (white arrows), high-attenuation infiltrates (black arrows), traction bronchiectases (white arrowheads) and honeycombing (black arrowheads) suggest amiodarone-induced pulmonary toxicity, in addition to emphysema (white asterisk).

References

- Schwaiblmair M, Berghaus T, Haeckel T, et al. Amiodarone-induced pulmonary toxicity: an under-recognized and severe adverse effect? *Clin Res Cardiol* 2010;99:693-700.
- Papiris SA, Triantafyllidou C, Kolilekas L, et al. Amiodarone: review of pulmonary effects and toxicity. *Drug Saf* 2010;33:539-58.
- Wolkove N, Baltzan M. Amiodarone pulmonary toxicity. *Can Respir J* 2009;16:43-8.