

# Efficacy and safety of the “mother’s kiss” technique: a systematic review of case reports and case series

Stephanie Cook BM BCh, Martin Burton DM, Paul Glasziou PhD

**Competing interests:** None declared.

This article has been peer reviewed.

**Correspondence to:**  
Stephanie Cook,  
steph\_cook@hotmail.com

*CMAJ* 2012. DOI:10.1503/  
cmaj.111864

## ABSTRACT

**Background:** Foreign bodies lodged in the nasal cavity are a common problem in children, and their removal can be challenging. The published studies relating to the “mother’s kiss” all take the form of case reports and case series. We sought to assess the efficacy and safety of this technique.

**Methods:** We performed a comprehensive search of the Cochrane library, MEDLINE, CINAHL, Embase, AMED Complementary and Allied Medicine and the British Nursing Index for relevant articles. We restricted the results to only those studies involving humans. In addition, we checked the references of relevant studies to identify further possibly relevant studies. We also checked current controlled trials registers and the World Health Organization search por-

tal. Our primary outcome measures were the successful extraction of the foreign object from the nasal cavity and any reported adverse effects. We assessed the included studies for factors that might predict the chance of success of the technique. We assessed the validity of each study using the Newcastle–Ottawa scale.

**Results:** Eight relevant published articles met our inclusion criteria. The overall success rate for all of the case series was 59.9% (91/152). No adverse effects were reported.

**Interpretation:** Evidence from case reports and case series suggests that the mother’s kiss technique is a useful and safe first-line option for the removal of foreign bodies from the nasal cavities of children.

Nasal foreign bodies are a common problem in children, most frequently occurring between the ages of 2 and 5 years, and their removal can be challenging.<sup>1,2</sup> Children in this age group have a natural fear of the unknown, and providing care to them can be difficult, especially if previous attempts to remove the foreign body have been painful.

Potential complications, most notably the risk of aspiration of the foreign body, mean that objects should be removed from the nasal cavity in a timely fashion. Various techniques have been described: instrumental extraction (using a hook or nasal forceps), suction, balloon catheters,<sup>3</sup> cyanoacrylate glue<sup>4</sup> and various positive-pressure techniques, the simplest of which is to ask the child to blow his or her nose while occluding the unaffected nostril. However, this technique is only possible for older children.<sup>5</sup> Alternatively, a bag valve mask can be applied over the child’s face, the bag then squeezed to apply a puff of air into the child’s mouth;<sup>6</sup> a male–male tube adaptor can be attached to an oxygen or air outlet via oxygen tubing placed in the unaffected nostril;<sup>7</sup> or the

“mother’s kiss” or “parent’s kiss” technique can be used.

The mother’s kiss was first described in 1965 by Vladimir Ctibor, a general practitioner from New Jersey.<sup>8</sup> The mother, or other trusted adult, places her mouth over the child’s open mouth, forming a firm seal as if about to perform mouth-to-mouth resuscitation. While occluding the unaffected nostril with a finger, the adult then blows until they feel the resistance caused by closure of the child’s glottis, at which point the adult gives a sharp exhalation to deliver a short puff of air into the child’s mouth. This puff of air passes through the nasopharynx, out through the unoccluded nostril and, if successful, results in the expulsion of the foreign body. The procedure is fully explained to the adult before starting, and the child is told that the parent will give him or her a “big kiss” so that minimal distress is caused to the child. The procedure can be repeated a number of times if not initially successful. A modified mother’s kiss technique has been described,<sup>9</sup> which involves the adult blowing into a straw in the child’s mouth. We did not include this technique in our review.

Although the mother's kiss technique has been sporadically mentioned in the literature in case reports and case series, it has yet to gain widespread acceptance. It is not a suitable intervention for evaluation using a randomized controlled trial, because there is no appropriate control group: nontreatment is unacceptable, and there is no gold standard for comparison.

Randomized controlled trials are considered to be the best trial design, but some treatments result in a dramatic effect that may not require randomized trials.<sup>10</sup> The mother's kiss technique falls into this category, because the foreign body will not usually move without intervention. Hence, case reports are sufficient to show that the technique sometimes works. However, a systematic review is needed to clarify how often it works and under what circumstances.

We sought to examine the existing evidence for the efficacy and safety of the mother's kiss technique, to help clinicians understand this evidence and to confirm or refute the appropriateness of current practice.

Although systematic reviews of randomized controlled clinical trials are now common, it is rare to see a report of a systematic review of case reports or case series, and the methods for performing such a review are less clearly defined and tested. The principal elements of a systematic review are the location, appraisal and synthesis of individual studies; however, there are pitfalls to traditional systematic reviews of clinical trials that can introduce bias and inaccuracy in the results, which must be avoided. For this systematic review of case reports and case series, we were ever mindful of the rationale behind the stages in systematic reviews of clinical trials and endeavoured to apply the same principles to reduce bias and improve accuracy.

**Box 1: Factors that might predict the success of the mother's kiss technique**

- Patient sex
- Patient age
- Patient race or ethnic background
- Location of foreign body or bodies (unilateral or bilateral)
- Type of foreign body (smooth, regular; irregular)
- Visibility of foreign body within the nasal cavity
- Length of time since insertion of the nasal foreign body
- Previous attempt(s) at removing the foreign body

## Methods

We reviewed studies that assessed whether the mother's kiss is an effective and safe technique for removing foreign bodies from the nasal cavities of children.

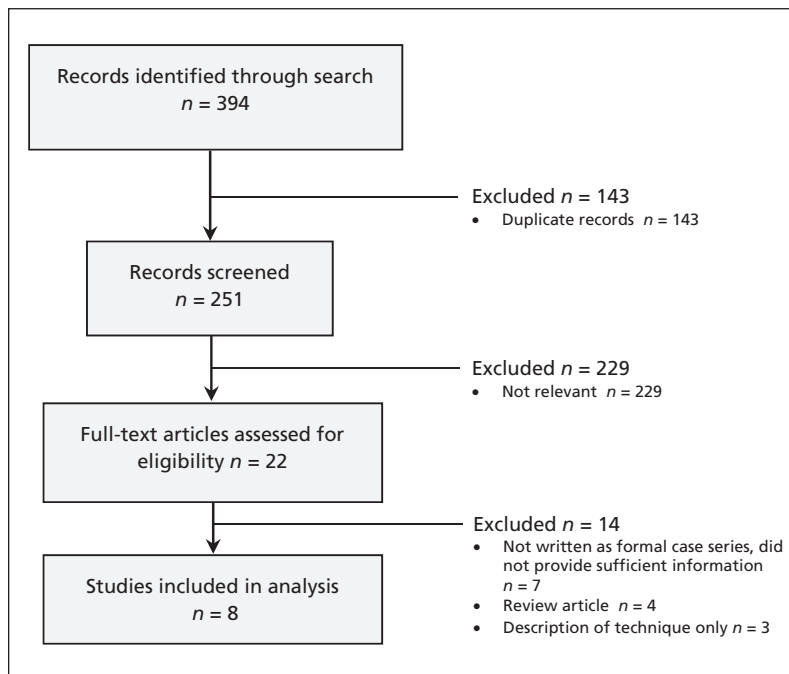
We searched the Cochrane Library, MEDLINE (1950 to present), CINAHL (1981 to present), Embase (1980 to present), AMED Allied and Complementary Medicine (1985 to present) and the British Nursing Index (1985 to present) for the following terms: "child or children," "pediatric," "nasal or nose" and "foreign body or bodies or object(s)," "mother," "father," "parent or parental," "magic," "reverse," "butterfly," "kiss or kissing," "blowing," "mouth-to-mouth" and "positive-pressure or positive pressure;" "removal" and "foreign body or object." We limited our results only to those studies involving humans, but we did not restrict the search by language or country of publication. We had the abstracts of any potentially relevant papers published in a language other than English translated; if they were still felt to be relevant, the whole paper was translated. See Appendix 1 for our comprehensive search strategy (available at [www.cmaj.ca/lookup/suppl/doi:10.1503/cmaj.111864/-/DC1](http://www.cmaj.ca/lookup/suppl/doi:10.1503/cmaj.111864/-/DC1)).

We screened the titles and abstracts of articles found during the search and retrieved any that were considered potentially relevant. We also checked the references of these articles to identify any additional possibly relevant studies. We included abstracts and correspondence in our searches of the references. In addition, we searched the current controlled trials registers and World Health Organization search portal. We attempted to clarify information in the relevant studies by communicating with the authors when necessary.

We assessed the validity of each included study using the Newcastle–Ottawa scale.<sup>11</sup> In addition, we assessed the design and quality of each study, including whether it was performed prospectively or retrospectively, whether the participants were enrolled consecutively or nonconsecutively, whether selection was based on a priori criteria, follow-up and blinding. Finally, we calculated the success rate of removal of the foreign body for each study.

Our primary outcome measures were the successful extraction of the foreign body from the nasal cavity and any reported adverse effects. Our secondary outcome measure was the reduction in the proportion of cases in which a general anesthetic was needed to remove the foreign body.

We included a study in our review if it met the following criteria: it included children with any type of foreign body in any location within the



**Figure 1:** The selection of studies included in the systematic review.

nasal cavity (i.e., visible or not), and it involved the mother's kiss or an equivalent technique.

We assessed the included studies for factors that might predict the success of the technique, including the age and sex of the child, the type of foreign body, the visibility of the foreign body in the nose, the length of time since insertion of the foreign body and any previous attempts at removal of the foreign body (Box 1). Other sources of clinical heterogeneity included the use of a topical vasoconstrictor or saline instilled into the nose before attempting to remove the foreign body, the exact technique employed (including the strength of the puff of air deployed into the child's mouth) and the number of attempts made to remove the foreign body using the mother's kiss technique.

## Results

We identified 22 relevant studies in our search. Of these studies, 8 met our inclusion criteria for the systematic review (Figure 1 and Table 1; a list of the excluded studies and reasons for their

**Table 1:** Validity assessment of included studies using the Newcastle–Ottawa Scale<sup>11</sup>

Study	Design	Setting; representiveness	Patients selected using a priori criteria	Level of training and supervision in the technique	Adverse effects and outcomes sought and documented systematically
Botma et al. 2000 <sup>1</sup>	Prospective/consecutive	Hospital emergency department; truly representative	Yes	Procedure explained to parents, performed under supervision of attending doctor	Yes
Purohit et al. 2008 <sup>12</sup>	Prospective/consecutive	Hospital emergency and ear, nose and throat departments; truly representative	Yes	Procedure clearly explained to parent	No, but stated that there were no complications
Backlin 1995 <sup>13</sup>	Retrospective	Hospital emergency department; somewhat representative	No	Instructions given to caregiver	Not specified, but none documented
Wagner 2003 <sup>14</sup>	Retrospective	Hospital emergency department, referred to otologist; somewhat representative	No	Parents instructed in the technique	No, but none documented
Taylor et al. 2010 <sup>15</sup>	Retrospective	Hospital pediatric emergency department; somewhat representative	No	Trained triage nurse on duty explained manoeuvre to parents	Yes, but none documented
Alleemudder et al. 2007 <sup>16</sup>	Not specified	Hospital emergency department; somewhat representative	No	Clear explanation given to parent, assistant held child	Not specified, but none documented
Hore 1996 <sup>17</sup>	Case report	Home; selected patient	No	Father was doctor and followed Backlin's description <sup>13</sup>	No, but none documented
Manca 1997 <sup>18</sup>	Case report	Home; selected patient	No	Mother was doctor experienced in technique	No, but none documented

Note: Items from the Newcastle–Ottawa scale not shown here include determining exposure (secure written records for all studies), length of follow-up sufficient for outcomes to occur (sufficient in all studies), assessment of outcome (unblinded, but objective for all studies) and adequacy of follow-up (complete for all studies).

**Table 2 (part 1 of 3):** Characteristics of the studies included in the systematic review

Study details; country	Age range; sex ratio	Previous attempt(s) at removal/total	Exact method used	Type of foreign body	Location of foreign body within nasal cavity; time since insertion	Person who performed the technique	Successes/total; no. of attempts using "mother's kiss"	Adverse effects reported; reduction in use of general anesthesia
<b>Case series</b>								
Botma et al., <sup>1</sup> prospective case series (19 patients); UK	1–5 yr, 12M:7F	10/19	Parent makes firm seal over child's open mouth and gives short, sharp puff of air into mouth while occluding unaffected nostril	Vegetable matter, sponge, bead, button, pebble, tissue paper, magnet	All objects visible on anterior rhinoscopy; 1 hr– 2 wk	Parent	15/19; vegetable matter (6/6), sponge (3/4), bead (2/3), button (1/2), pebble (2/2), tissue paper (1/1), magnet (0/1); not specified	None; not reported
Purohit et al., <sup>2</sup> prospective case series (31 patients); UK	< 5 yr, (mean age 33 mo, median 24 mo), 19M:12F	14/31	Parent's kiss (parent makes firm seal around child's partially open mouth, and delivers a short, sharp puff of air, while occluding the unobstructed nostril with a thumb; repeated max. 5 times)	17 small, smooth, spherical objects (e.g., peas, beads), 13 large, irregular objects (e.g., paper, plastic)*	Object not visible in 4 cases, 2 of which were removed by parent's kiss; other 2 became visible after parent's kiss, allowing removal with hook; 30 min– 7 d	Parent	20/31 (removal aided by mother's kiss in 2 other cases); (13/17 small smooth spherical objects; 7/13 large irregular objects); not specified (up to 5 attempts)	None; rate reduced from 32.5% to 3.2% over 6-mo period after technique introduced
Backlin, <sup>13</sup> retrospective case series (8 patients); Canada	2–4 yr; 3M:5F	Not specified	Topical vasoconstrictor applied if edema or bleeding; child positioned supine; caregiver gives a puff of "mouth-to-mouth" while occluding the unobstructed nostril with a finger	Beads (2), sunflower seed, plastic doll shoe, styrofoam chip, plastic toy piece, popcorn kernel, crayon piece	Location not specified; time unknown for 1 case, all others brought immediately to hospital	Caregiver	8/8; not specified	None; not reported

**Table 2 (part 2 of 3):** Characteristics of the studies included in the systematic review

Study details; country	Age range; sex ratio	Previous attempt(s) at removal/total	Exact method used	Type of foreign body	Location of foreign body within nasal cavity; time since insertion	Person who performed the technique	Successes/total; no. of attempts using "mother's kiss"	Adverse effects reported; reduction in use of general anesthesia
Wagner, <sup>14</sup> retrospective case series (2 patients); Denmark	1.5 and 2.5 yr; 2M:0F	2/2	The parents are instructed in the method; they tell the child that he or she is to have a huge kiss in which air will be blown into the mouth; the parent closes his or her lips around the open mouth of the child (e.g., "mouth-to-mouth resuscitation"; the unaffected nostril is obstructed by a parent's finger; swift vigorous pressure is applied while kissing, and the FB is blown out; the procedure may be repeated several times before success; after, the doctor ensures that the FB is out)	Piece of wiener sausage, small stone	Right posterior naris, other not specified; time since insertion not specified	Parent	2/2 (stone removed after 3 attempts); not specified	None; not reported
Taylor et al., <sup>15</sup> retrospective case series (84 patients); UK	1-8 yr (median 2 yr); 31M:53F	Not specified	Done by the parent under instruction from a trained member of staff; the parent puts his or her mouth over the child's (giving a "big kiss") and occludes the unaffected nostril with 1 finger; the parent then exhales into the child's mouth, generating positive pressures, similar to that of nose blowing	Food (18), toys (47), materials (17), not documented (2)	Left nostril (30), right nostril (53), bilateral (1), exact location not specified; time not specified, but average time spent in ED 67.7 min	Parent	41/84; not specified	None; use of anesthesia lower when compared with cases in which the technique was not attempted (11.9% v. 18.8%)

**Table 2 (part 3 of 3):** Characteristics of the studies included in the systematic review

Study details; country	Age range; sex ratio	Previous attempt(s) at removal/total	Exact method used	Type of foreign body	Location of foreign body within nasal cavity; time since insertion	Person who performed the technique	Successes/total; no. of attempts using "mother's kiss"	Adverse effects reported; reduction in use of general anesthesia
Alleemudder et al., <sup>16</sup> case series (8 patients), UK	2–7 yr; 4M:4F	Not specified	Positive pressure technique, fully explained to parent before procedure; child told that a "big kiss" would be given; child held sitting semi-recumbent; parent applies finger pressure on ala of unaffected nostril to occlude it; parent blows air forcibly into child's mouth to dislodge FB forward and out of nostril	Toy part, sponge, eraser, pea, plastic beads (2), rubber tire, raisin	Location not specified; time since insertion not specified	Parent	5/8; 1–4 attempts	None; not reported
<b>Case reports</b>								
Hore, <sup>17</sup> case report (letter); UK	3 yr; 1F	0/1	Parent's kiss as described by Backlin <sup>13</sup> (child lies on back and opens mouth; unaffected nostril occluded with finger, firm seal made around child's mouth by parent's mouth and short puff of air delivered into child's mouth to expel the FB)	Small polystyrene bead	Object just visible in right nostril; time not specified, but attempt made soon after insertion	Father	1/1; not specified	None; not specified
Manca, <sup>18</sup> description of technique and case report; Canada	5 yr; 1F	0/1	Parent's kiss (pressure applied to unaffected nostril, brisk blow into child's mouth, forcing air out of the affected nostril)	White scented bead	Bead just visible in nostril; time not specified, but attempt made immediately after insertion	Mother	1/1; not specified	None; not specified

Note: ED = emergency department, F = female, FB = foreign body, M = male.

\*Discrepancy between number of patients and number of objects successfully removed appears in original study by Purohit et al. Attempts to contact authors of original study for clarification were unsuccessful.

exclusion is provided in Appendix 2, available at [www.cmaj.ca/lookup/suppl/doi:10.1503/cmaj.111864/-/DC1](http://www.cmaj.ca/lookup/suppl/doi:10.1503/cmaj.111864/-/DC1).<sup>1,11-18</sup> Two of these studies were prospective case series with consecutive enrolment of patients,<sup>1,12</sup> 3 were retrospective case series,<sup>13-15</sup> 1 was a case series for which it was unclear whether it was prospective or retrospective,<sup>16</sup> and 2 were case reports<sup>17,18</sup> (Table 2). We excluded 14 studies, 7 of which were not written as formal case series and did not provide sufficient information to allow us to assess them adequately (such as success rates), 4 were review articles, and 3 gave only a description of the technique.

Of the included studies, 1 retrospective case series was a Danish paper that had to be translated into English.<sup>14</sup> We identified no randomized controlled trials or systematic reviews in our search.

### Primary outcome measures

When we combined the results of all of the case series, the technique was effective about 60% of the time (95% confidence interval [CI] 52%–67%) (Table 3). We saw no significant difference in the

success rate of removing the foreign body based on the type of object (73% [95% CI 56%–86%] for smooth regular objects v. 77% [95% CI 62%–87%] for irregular objects). Insufficient information was given in the studies for us to perform subgroup analyses on the efficacy of the technique in relation to the length of time since insertion of the foreign body, its visibility or whether there had been any previous attempts at removal.

No adverse effects were reported in using the mother's kiss technique in any of the published studies.

### Secondary outcome measures

Only 2 studies<sup>12,15</sup> reported the rates with which general anesthesia was used. Purohit and colleagues showed a reduction from 32.5% to 3.2% over an equivalent 6-month period before and after the mother's kiss technique was introduced, and Taylor and colleagues showed a lower rate of general anesthesia (11.9% v. 18.8%,  $\chi^2 = 0.91$ ,  $p = 0.34$ ) when compared with cases for which the technique was not attempted.

### Predictive factors

Cases were similar in terms of the ages of the patients (1–8 yr). Where stated, most of the foreign bodies were visible in the nose before removal was attempted, with just 4 out of 31 cases in a single study<sup>12</sup> in which the foreign body was not visible. No information was given on the ethnic backgrounds of the children involved in any of the studies.

### Interpretation

Our review suggests that the mother's kiss technique is effective.

We saw no significant difference in the success of the technique when used to remove smooth regular objects versus irregular objects. However, 2 of the included studies stated that a fully obstructing object is much more likely to be propelled out of the nose than an irregularly shaped object that spans the nostril but permits air to pass.<sup>13,16</sup> In addition, irregularly shaped objects tend to be easier to grasp.

Any difference in success rates between studies may be due to different settings. For example, 4 of the included studies only involved children presenting to the emergency department, which may deal with less complicated cases than would an ear, nose and throat specialist.<sup>1,13,15,16</sup>

Although the overall number of children who had a previous attempt at removal of the foreign body before the mother's kiss was attempted was given in all but 3 of the studies,<sup>13,15,16</sup> there was no attempt to correlate these numbers with the subse-

**Table 3:** Overall rates of success for the mother's kiss technique in the 8 included studies

Study	Success rate, % (n/N)	Type of object	
		Smooth, regular	Irregular
<b>Case series</b>			
Botma et al. <sup>1</sup>	79 (15/19)	5/7 (beads, buttons, pebbles)	10/12 (vegetable matter, sponge, tissue paper, magnet)
Purohit et al. <sup>12*</sup>	65 (20/31)	13/17	7/13
Backlin <sup>13</sup>	100 (8/8)	2/2 (beads)	6/6 (sunflower seed, plastic doll's shoe, Styrofoam chip, plastic toy piece, popcorn kernel, crayon piece)
Wagner <sup>14</sup>	100 (2/2)		2/2 (piece of wiener sausage, small stone)
Taylor et al. <sup>15</sup>	49 (41/84)	Not specified	Not specified
Alleemudder et al. <sup>16</sup>	63 (5/8)	0/2 (plastic beads)	5/6 (toy part, sponge, eraser, pea, rubber tire, raisin)
<b>Case reports</b>			
Hore <sup>17</sup>	100 (1/1)	1/1 (small polystyrene bead)	
Manca <sup>18</sup>	100 (1/1)	1/1 (white scented bead)	
*Discrepancy between number of patients and number of objects removed appears in original study by Purohit et al. Attempts to contact the authors of the original study for clarification were unsuccessful.			

quent successfulness of the technique. In addition, the length of time since an object's insertion and the location of the object in the nasal cavity are likely to be important factors in successful removal. Foreign bodies that are visible and relatively anterior are likely to be easier to remove than more posterior nonvisible objects. Unfortunately, none of the included studies provided information with sufficient detail for either of these factors to be analyzed further, and our attempts to contact the authors to obtain further information were unsuccessful.

No adverse events were reported in the included studies, although a number of theoretical risks of the technique have been documented, such as barotrauma, both to the tympanic membranes and to the lower airways.<sup>16,17,19-21</sup> However, a ruptured tympanic membrane or pneumothorax resulting from this technique has never been reported. The glottis is closed during the technique, so there is little risk of barotrauma to the lungs. Furthermore, the pressure used is low, comparable with that generated during sneezing (about 60 mm Hg). The main danger in removing a foreign body from the nose by any technique is aspiration, particularly in a child who is uncooperative. However, no epistaxes were reported postprocedure in the study by Taylor and colleagues,<sup>15</sup> and 2 studies stated that all of the parents felt that the technique was acceptable.<sup>13,15</sup> Thus, although theoretically possible, no actual adverse effects were reported.

### Limitations

The absence of a search strategy optimized for the detection of case reports and case series (such as those optimized for randomized controlled clinical trials) should be noted. Because many case reports and case series lack an abstract or have noninformative titles, it is possible that our search may have missed some reports. However, because the name of the intervention we studied is so unusual, one could reasonably hope to identify all of the publications relating to it and screen out any that are irrelevant. Thus, not having a filter for study type in the early stages of our search likely did not affect our results, because our goal was to identify every article involving this technique.

Publication bias is a potential problem in systematically reviewing case reports and, to a lesser extent, case series. Positive results tend to be published more frequently than negative results — case reports are very unlikely to be written and published if a technique is unsuccessful. In the retrospective case series included in our review, any failed attempts at using the mother's kiss may not have been recorded in the notes, with only the successful alternative method recorded. The retrospective studies we identified recorded a 54%

success rate, compared with 70% for the prospective studies. Thus, although any result combining both prospective and retrospective studies is likely to give an overestimation of effect, this was not the case for our study.

Reporting bias is an additional issue, with either successful or failed cases not being reported owing to clinicians' other priorities. In an attempt to address this issue, we emailed a group of 1150 British ear, nose and throat surgeons about the mother's kiss technique to identify any unpublished studies and gain additional information about the success of the technique. We identified no new unpublished studies.

### Conclusion

The mother's kiss appears to be a safe and effective technique for first-line treatment in the removal of a foreign body from the nasal cavity. In addition, it may prevent the need for general anesthesia in some cases.

Further studies are needed to compare different positive-pressure techniques, and to test their efficacy in specific situations addressing how long the foreign body has been lodged and its location in the nasal cavity. To reduce the impact of selective reporting, such future research should involve preregistered, large, consecutive, prospective case series.

### References

1. Botma M, Bader R, Kubba H. 'A parent's kiss': evaluating an unusual method for removing nasal foreign bodies in children. *J Laryngol Otol* 2000;114:598-600.
2. François M, Harioui R, Narcy P. Nasal foreign bodies in children. *Eur Arch Otorhinolaryngol* 1998;255:132-4.
3. Nandapalan V, McIlwain JC. Removal of nasal foreign bodies with a Fogarty biliary balloon catheter. *J Laryngol Otol* 1994;108:758-60.
4. Hanson RM, Stephens M. Cyanoacrylate-assisted foreign body removal from the ear and nose in children. *J Paediatr Child Health* 1994;30:77-8.
5. Messervy M. Forced expiration in the treatment of nasal foreign bodies. *Practitioner* 1973;210:242.
6. Finkelstein JA. Oral ambubag insufflation to remove unilateral nasal foreign bodies. *Am J Emerg Med* 1996;14:57-8.
7. Navitsky RC, Beamsley A, McLaughlin S. Nasal positive-pressure technique for nasal foreign body removal in children. *Am J Emerg Med* 2002;20:103-4.
8. Guazzo E. Removal of foreign bodies from the nose. *N Engl J Med* 1985;312:725.
9. Benjamin E, Harcourt J. The modified 'Parent's Kiss' for the removal of paediatric nasal foreign bodies. *Clin Otolaryngol* 2007;32:120-1.
10. Glasziou P, Chalmers I, Rawlins M, et al. When are randomised trials unnecessary? Picking signal from noise. *BMJ* 2007;334:349-51.
11. Wells GA, Shea B, O'Connell D, et al. The Newcastle-Ottawa Scale (NOS) for assessing the quality of nonrandomised studies in metaanalyses. [http://www.ohri.ca/programs/clinical\\_epidemiology/oxford.htm](http://www.ohri.ca/programs/clinical_epidemiology/oxford.htm) (accessed 2006 Mar. 21).
12. Purohit N, Ray S, Wilson T, et al. The 'parent's kiss': an effective way to remove paediatric nasal foreign bodies. *Ann R Coll Surg Engl* 2008;90:420-2.
13. Backlin SA. Positive pressure technique for nasal foreign body removal in children. *Ann Emerg Med* 1995;25:554-5.
14. Wagner N. "Kiss the child" Removal of nasal foreign bodies in children using the mouth-to-mouth method. [Danish]. *Ugeskr Laeger* 2003;165:2662-3.
15. Taylor C, Acheson J, Coats TJ. Nasal foreign bodies in children: kissing it better. *Emerg Med J* 2010;27:712-3.



16. Alleemudder D, Sonsale A, Ali S. Positive pressure technique for removal of nasal foreign bodies. *Int J Pediatr Otorhinolaryngol* 2007;71:1809-11.
17. Hore CT. Nasal foreign body removal in children. *Med J Aust* 1996;164:448.
18. Manca D. Up your nose. Quick and somewhat dirty method of removing foreign bodies from children's noses. *Can Fam Physician* 1997;43:223.
19. Chan TC, Ufberg J, Harrigan RA, et al. Nasal foreign body removal. *J Emerg Med* 2004;26:441-5.
20. Davies PH, Bengier JR. Foreign bodies in the nose and ear: a review of techniques for removal in the emergency department. *J Acc Emerg Med* 2000; 17:91-4.
21. Fallis GB, Ferguson K, Waldman M. Simple technique for removing foreign bodies from the nose. *Am Fam Phys* 1992; 46:1046-51.

**Affiliations:** From Buxted Medical Centre (Cook), Buxted, UK; the Oxford University Hospitals National Health Ser-

vice Trust (Burton), the UK Cochrane Centre (Burton) and the Ear, Nose and Throat Department (Burton), John Radcliffe Hospital, Oxford, UK; and the Centre for Research in Evidence-Based Practice (Glasziou), Bond University, Gold Coast, Australia

**Contributors:** Martin Burton conceived the idea for the study. Stephanie Cook drafted the manuscript. Martin Burton and Paul Glasziou revised the manuscript for important intellectual content. All of the authors analyzed and interpreted the data and approved the final manuscript submitted for publication.

**Acknowledgements:** The authors would like to thank Dr. Christian Hermann for his help in translating the Danish study by Wagner, Mrs. Clare Phillips for her help in translating the French study by Claudet and colleagues, and Gemma Sandberg and Samantha Faulkner at the UK Cochrane Collaboration for their help with the search.