

## CLINICAL IMAGES

## Crowned dens syndrome

Akira Kuriyama MD MPH

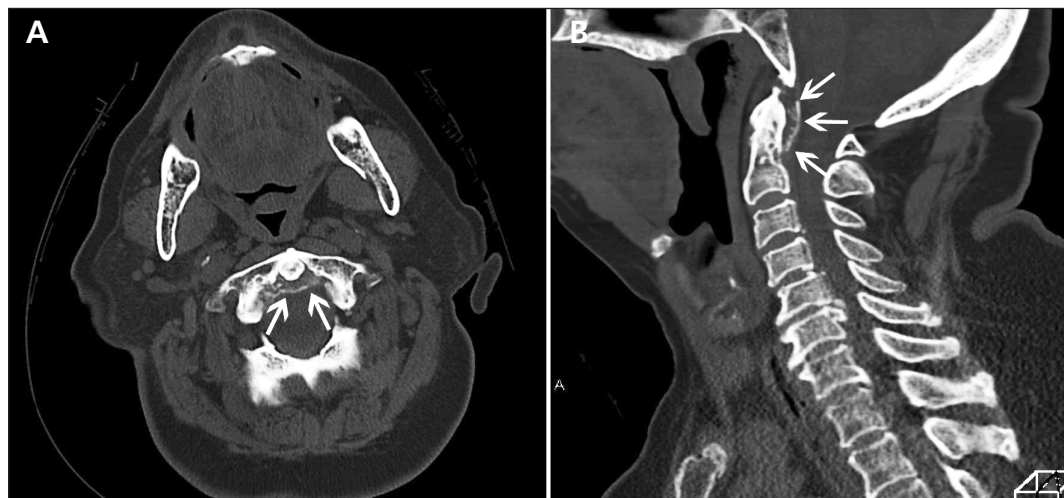


Figure 1: (A) Thin curvilinear calcification (arrow) of the transverse ligament of the atlas. (B) Linear calcification (arrows) in the coronal view.

An 84-year-old man presented with acute fever, occipital pain and neck stiffness. His medical history included pseudogout of the right knee, which was confirmed by the presence of chondrocalcinosis on a radiograph and calcium pyrophosphate dihydrate crystals in fluid obtained by arthrocentesis. His mentation was normal, and he had limited cervical motion in all directions. His erythrocyte sedimentation rate was 100 mm/h, and his C-reactive protein level was 1152 (normal < 28.5) nmol/L. Analysis of his cerebrospinal fluid showed no pleocytosis, which argued against inflammation, infection or malignant disease involving the central nervous system. Computed tomography of the neck showed calcification of the transverse ligament of the atlas (Figure 1), consistent with a diagnosis of crowned dens syndrome.

Crowned dens syndrome is characterized by neck pain and stiffness due to crown-shaped calcification around the odontoid process. The prevalence of this syndrome is unclear. According to one single-centre study involving 40 patients, it may be identified in up to 5% of adults over the age of 70 who present to hospital

with neck pain as the chief complaint.<sup>1</sup> Importantly, it sometimes presents with fever and neck stiffness and mimics meningitis.<sup>2</sup> Inflammatory indices are elevated, as is seen in most cases of crystal-induced arthritis.<sup>1,3</sup> The differential diagnosis of transverse-ligament calcification includes hydroxyapatite deposition and pseudogout. However, most patients with crowned dens syndrome have experienced pseudogout of other joints,<sup>1,3</sup> and the presence of pseudogout makes this diagnosis more likely. Case series have reported dramatic clinical improvement with short-term administration of nonsteroidal anti-inflammatory drugs, steroids or colchicine.<sup>1,2</sup>

In the case of this patient, loxoprofen therapy for one week led to complete resolution of the symptoms and normalization of the inflammatory indices.

## References

- Goto S, Umehara J, Aizawa T, et al. Crowned dens syndrome. *J Bone Joint Surg Am* 2007;89:2732-6.
- Aouba A, Vuillemin-Bodaghi V, Mutschler C, et al. Crowned dens syndrome misdiagnosed as polymyalgia rheumatica, giant cell arteritis, meningitis or spondylitis: an analysis of eight cases. *Rheumatology (Oxford)* 2004;43:1508-12.
- Roverano S, Ortiz AC, Ceccato F, et al. Calcification of the transverse ligament of the atlas in chondrocalcinosis. *J clinical rheumatol* 2010;16:7-9.

**Competing interests:** None declared.

This article has been peer reviewed.

**Affiliations:** Department of General Medicine, Kurashiki Central Hospital, Okayama, Japan; Department of General Internal Medicine, Rakuwakai Otowa Hospital, Kyoto, Japan

**Correspondence to:** Akira Kuriyama, nrk40448@nifty.com

**CMAJ 2014. DOI:10.1503/cmaj.122147**