

Cancer Research



Experimental Transmission of a Plasmacytoid Leukemia of Chinook Salmon, *Oncorhynchus tshawytscha*

Michael L. Kent and Sheila C. Dawe

Cancer Res 1990;50:5679s-5681s. Published online September 1, 1990.

Updated Version

Access the most recent version of this article at:
http://cancerres.aacrjournals.org/content/50/17_Supplement/5679s

E-mail alerts

Sign up to receive free email-alerts related to this article or journal.

Reprints and Subscriptions

To order reprints of this article or to subscribe to the journal, contact the AACR Publications Department at pubs@aacr.org.

Permissions

To request permission to re-use all or part of this article, contact the AACR Publications Department at permissions@aacr.org.

Experimental Transmission of a Plasmacytoid Leukemia of Chinook Salmon, *Oncorhynchus tshawytscha*¹

Michael L. Kent² and Sheila C. Dawe

Department of Fisheries and Oceans, Biological Sciences Branch, Pacific Biological Station, Nanaimo, British Columbia V9R 5K6, Canada

Abstract

A plasmacytoid leukemia of chinook salmon, *Oncorhynchus tshawytscha*, has recently been recognized in seawater netpens in British Columbia, Canada. The disease has occurred at several sites and has caused high mortality. Plasmacytoid leukemia is characterized by a generalized invasion of visceral tissues and the orbit of the eye by plasmacytoid cells. The disease was experimentally transmitted to healthy chinook salmon by i.p. injection of kidney tissue homogenates, but transmission with a cell-free filtrate was equivocal. In another experiment, chinook salmon, coho salmon, *O. kisutch*, sockeye salmon, *O. nerka*, rainbow trout, *O. mykiss* (or *Salmo gairdneri*), and Atlantic salmon, *Salmo salar*, were given injections of a tissue homogenate from affected chinook salmon. Ten wk after exposure, plasmacytoid leukemia was observed in all of the sockeye salmon and chinook salmon, one of ten Atlantic salmon, and none of the rainbow trout. Seven of the ten coho salmon examined at 10 wk had lesions suggestive of early development or a mild form of the disease. Multifocal areas of proliferating cells resembling plasmablasts were observed in the visceral fat, and the kidneys exhibited mild to moderate hyperplasia of the hematopoietic interstitium. Our studies support the hypothesis of an infectious etiology for plasmacytoid leukemia, but the agent, perhaps an oncogenic virus, has yet to be detected.

Introduction

Commercial rearing of salmonid fishes in seawater netpens is an important growing industry in British Columbia, Canada. In British Columbia, the chinook salmon, *Oncorhynchus tshawytscha*, is the primary species reared in netpens, and the estimated harvest for 1989 was approximately 14,000 metric tons. With the increase in this relatively new form of aquaculture, several new diseases of cultured salmonids have been reported (1).

An apparently new disease of pen-reared salmon, referred to as "marine anemia" by fish farmers, has recently caused severe losses in chinook salmon reared at several sites in British Columbia. The disease was first recognized in the fall of 1988, when unusual mortality was observed in market-size fish. The disease is suggestive of leukemia, with massive infiltration of essentially all organs by immature blood cells that resemble plasmablasts. Apparently the same disease was first observed in chinook salmon fingerlings reared in a freshwater hatchery in Washington state. Fish from this epizootic were submitted to the Registry of Tumors in Lower Animals, Smithsonian Institute, Washington, DC (RTLA Accession Nos. 1022 and 1023), and the histological features of this disease were consistent with acute granulocytic or erythrocytic leukemia (2, 3). Our results, however, indicated that the disease is a PL,³ and henceforth the proliferating cells are referred to as plasmablasts. We have previously described the gross, histological, and cytological characteristics of PL of chinook salmon (4). In this

paper we describe experimental transmission of the disease to chinook salmon and other salmonid fishes.

Materials and Methods

Experiment 1: Transmission to Chinook Salmon. Apparently healthy chinook salmon (average weight, 40 g) from seawater netpens at the Pacific Biological Station (Nanaimo, British Columbia) were used as recipients in this experiment. Fish were transferred to open system seawater tanks maintained at a salinity of approximately 30 ppt at 9–12°C. Each exposure group was maintained in a separate tank.

These fish were exposed to a homogenate and 0.22- μ m filtrate by the following method. Kidney tissues from 3 fish with PL were pooled, diluted 1:4 in MEM, and thoroughly homogenized with a Polytron homogenizer (Brinkman Instruments, Westburg, NY). The homogenate was examined in wet mount preparations to ensure that there were no intact cells. The cell-free filtrate was prepared by centrifugation of the homogenate at 1000 \times g for 10 min, followed by filtration through a Millipore 0.22- μ m filter (Millipore Corporation, Bedford, MS). The filter was pretreated with MEM containing 10% serum. Thirty-six fish were given injections of the homogenate, 15 fish were given injections of the filtrate, and 20 control fish were given injections of MEM. All fish received 0.5 ml/fish of the appropriate inoculum.

Experiment 2: Interspecies Transmission. Sixteen apparently healthy chinook salmon (average weight, 46 g), 25 sockeye salmon, *O. nerka* (average weight, 37 g), 23 coho salmon, *O. kisutch* (average weight, 20 g), 26 rainbow trout, *O. mykiss* (or *Salmo gairdneri*) (average weight, 45 g), and 22 Atlantic salmon, *Salmo salar* (average weight, 21 g), which were maintained in fresh water at the Pacific Biological Station, were used as recipients for this experiment. Each species was exposed as described in Experiment 1 to a homogenate of affected kidney tissue from a chinook salmon with PL. Fishes were maintained together in a freshwater, open system aquarium at 10°C. Twenty controls for each species were maintained in a separate aquarium. After 1 wk, the fishes were acclimated to brackish seawater (approximately 20 ppt) at 9–11°C.

Tissue from all fishes examined in both experiments was preserved in Davidson's solution (5), processed for histology, and examined by light microscopy.

Results

In Experiment 1, bacterial skin lesions, caused by a *Cytophaga* sp. (Order Cytophagales), were observed in the exposed and control fish shortly after the experiment was initiated. Mortality occurred in all three groups at 1 to 3 wk post injection as a result of these lesions. Histological examinations of these fish showed no signs of PL. Twelve fish in the homogenate group survived longer than 3 wk, and all of these fish exhibited severe PL between 3 and 7 wk post injection. As observed in affected fishes from the field, the fish were anemic and had swollen kidneys and spleens. Histological examination of these fishes showed massive proliferation of the plasmablasts in the visceral organs, including liver, kidney interstitium, spleen, lamina propria of the intestine and pyloric caeca, pancreas, and mesenteric fat (Figs. 1 and 2). Ten surviving fishes in the filtrate group were examined between 4 and 12 wk post injection. None of these fish exhibited typical gross or histological signs of PL. However, one fish from the filtrate group, exam-

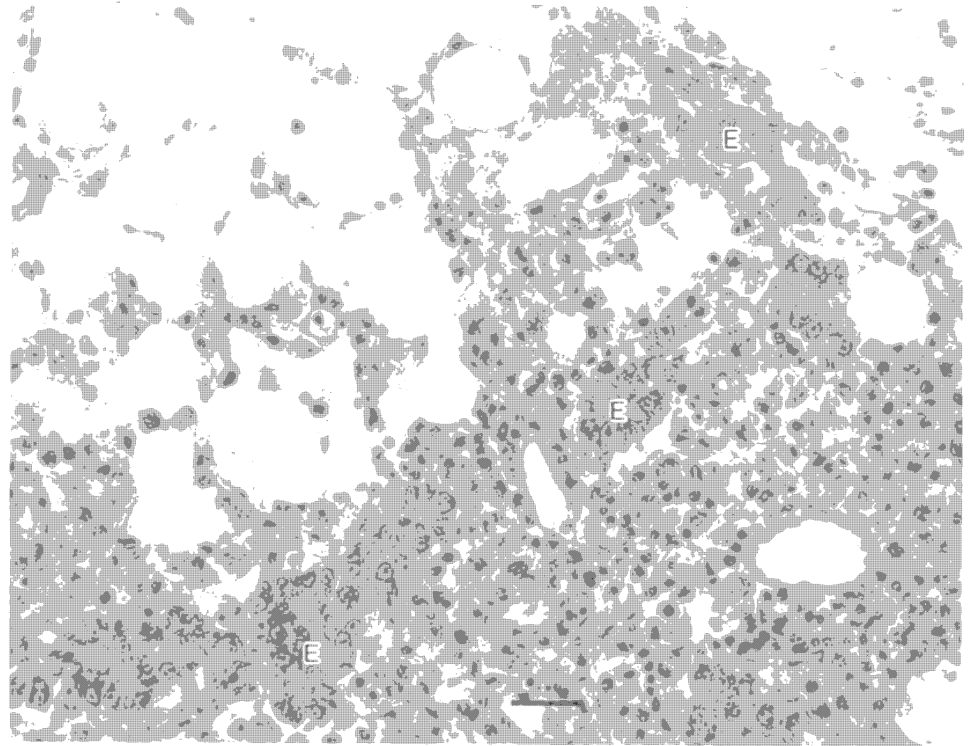
¹ Presented at the "XIVth Symposium of the International Association for Comparative Research on Leukemia and Related Diseases," October 8–12, 1989, Vail, CO.

Supported in part by the Ministry of Agriculture and Fisheries, Commercial Fisheries and Aquaculture Branch, Province of British Columbia, Canada.

² To whom requests for reprints should be addressed.

³ The abbreviations used are: PL, plasmacytoid leukemia; MEM, minimal essential medium.

Fig. 1. Exocrine pancreas (E) and mesenteric fat infiltrated with proliferating plasma-blasts in a chinook salmon with PL. H & E; bar, 40 μ m.



ined at 7 wk post injection, exhibited nests of cells in the liver, suggestive of the plasmablasts. Histological examination of ten surviving control fishes at 12 wk post injection revealed no evidence of the disease.

In the interspecies transmission study (Experiment 2), one coho salmon and two Atlantic salmon died immediately after injection. At 42 days post injection, the first chinook salmon exhibited morbidity, and histological examination revealed severe PL. Eleven chinook salmon died or were collected when moribund before the fishes were sampled at 10 wk post injection, and all of these exhibited severe PL. At 10 wk, all remaining chinook (5 fish) exhibited PL. Ten fishes of each of the

other species were also examined at 10 wk post injection. Although the other species appeared clinically normal, PL was detected by histology in all 10 sockeye salmon and in one of the ten Atlantic salmon. Seven of the coho salmon and one of the rainbow trout had lesions that were suggestive of the early stages or of a mild form of the disease. Multifocal areas of proliferating cells resembling plasmablasts were observed in the visceral fat, and the kidneys exhibited mild to moderate hyperplasia of the hematopoietic interstitium. No control fishes exhibited histological signs of PL.

Discussion

These transmission studies indicate that PL is caused by an infectious agent. Plasma cell neoplasms have been reported from six species of fishes. Plasmacytomas have been reported from pike, *Esox lucius*, muskellunge, *E. masquinongy*, channel catfish, *Ictalurus punctatus*, largemouth bass, *Micropterus salmoides*, and sleeper goby, *Oxyeleotris marmorata* (3), and a plasma cell leukemia was observed in brown bullhead, *I. nebulosus* (6). This leukemia cell was transmissible with cell-free filtrates, with onset of the disease at about 10 wk post injection (6, 7). A retroviral etiology was suggested for this disease, and reverse transcriptase activity was detected in affected tissues (6). Most hematopoietic neoplasms described in fishes have been lymphomas (3), and at least one is apparently caused by a retrovirus. A lymphoma of pike, *E. lucius*, was transmitted with cell-free material (8–10), and reverse transcriptase and C-type retroviruses were associated with the neoplasms (11).

Plasmacytoid leukemia of chinook salmon was transmitted with tissue homogenates, but transmission with cell-free filtrates was equivocal. However, this does not exclude the possibility that PL of chinook salmon has a viral etiology. It is possible that the putative virus is cell associated and/or that the concentration of the agent was greatly reduced by filtration, as occurs with certain retroviral leukemias of higher animals (e.g.,

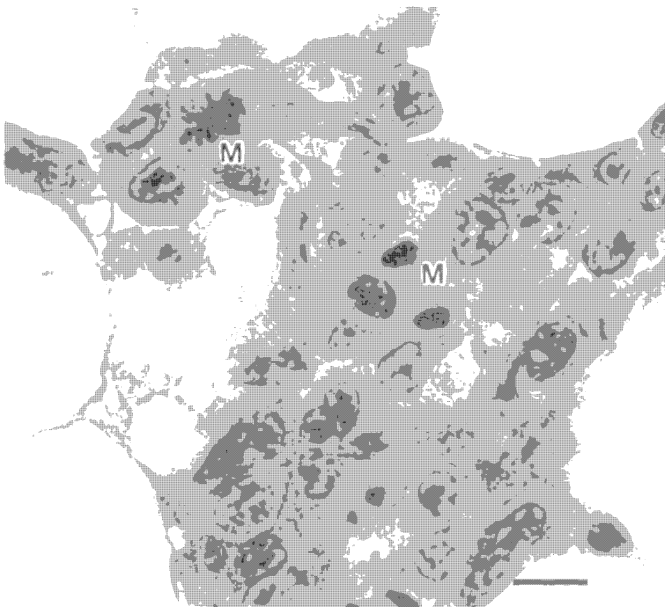


Fig. 2. Plasmablasts in mesenteric fat of a chinook salmon with PL. Two cells are undergoing mitosis (M). H & E; bar, 10 μ m.

bovine leukosis). Additionally, type A retroviruses are associated with plasma cell neoplasms of mice, but the tumors are often difficult to transmit with cell-free material (12). It is likely that PL was transmitted in our study by an infectious agent, rather than transplanted with whole cells, because the inoculum was thoroughly homogenized and apparently contained no intact cells. Moreover, the donor and recipient chinook salmon were not syngeneic, and the occurrence of the disease in the other salmonids represents interspecific transmission. The epizootiological pattern of the disease, with apparent transmission between year classes at affected sites (4), also suggests that PL is caused by an infectious agent.

We have yet to visualize virus particles in affected fish, and examination for viruses and reverse transcriptase activity is underway on primary cultures of the plasmablasts maintained under various culture conditions. The disease continues to be widespread in netpen-reared chinook salmon, and identification of the etiological agent will be a primary focus of our research on this disease.

References

1. Kent, M. L., and Elston, R. A. Diseases of seawater reared salmon in Washington state. In: S. Keller (ed.), Proceedings of the Fourth Alaska Aquaculture Conference, No. 88-4, pp. 161-163. Fairbanks: Alaska Seagrass College Program, 1987.
2. Harshbarger, J. C. Pseudoneoplasms in ectothermic animals. Natl. Cancer Inst. Monogr., 65: 251-273, 1984.
3. Frederickson, T. N., Walsh, A. H., and Wolke, R. E. Tumors of the lymphoid and other hemopoietic tissues. In: C. Dawe, J. C. Harshbarger, S. R. Wellings, and J. Strandburg (eds.), Pathobiology of Spontaneous and Induced Neoplasms in Fishes: Morphology, Comparative Characterization, and Literature. New York: Academic Press, in press, 1990.
4. Kent, M. L., Groff, J. M., Traxler, G. S., Zinkl, J. G., and Bagshaw, J. W. Plasmacytoid leukemia in seawater reared chinook salmon, *Oncorhynchus tshawytscha*. Dis. Aquat. Org., in press, 1990.
5. Humason, G. L. Animal Tissue Techniques. San Francisco: W. H. Freeman Co., 1979.
6. Sonstegard, R. A. Virus associated hematopoietic neoplasia in shellfish and fish. In: D. S. Yohn, B. A. Lapin, and J. R. Blakeslee (eds.), Advances in Comparative Leukemia Research, p. 227. New York: Elsevier North Holland, Inc., 1980.
7. Gross, L. Tumors, leukemia, and lymphosarcomas in fish. In: L. Gross (ed.), Oncogenic Viruses, Ed. 3, pp. 103-116. Elmsford, NY: Pergamon Press, 1983.
8. Mulchay, M. F., and O'Leary, A. Cell-free transmission of lymphosarcoma in the northern pike, *Esox lucius* L. (Pisces; Esocidae). Experientia (Basel), 26: 891, 1970.
9. Brown, E. R., Keith, L., Hazdra, J. J., and Arndt, T. Tumors in fish caught in polluted waters: possible explanations. In: Y. Ito and R. M. Dutcher (eds.), Comparative Leukemia Research 1973, Leukemogenesis, pp. 47-57. Tokyo: University of Tokyo Press, 1975.
10. Sonstegard, R. A. Studies of the etiology and epizootiology of lymphosarcoma in *Esox* (*Esox lucius* L. and *Esox masquinongy*). Prog. Exp. Tumor Res., 20: 141-155, 1976.
11. Papas, T. S., Dahlberg, J. E., and Sonstegard, R. A. Type C virus in lymphosarcoma in northern pike (*Esox lucius*). Nature (Lond.), 261: 506-508, 1976.
12. Potter, M. Immunoglobulin-producing tumors and myeloma proteins of mice. Physiol. Rev., 52: 631-719, 1972.

Cancer Research



Experimental Transmission of a Plasmacytoid Leukemia of Chinook Salmon, *Oncorhynchus tshawytscha*

Michael L. Kent and Sheila C. Dawe

Cancer Res 1990;50:5679s-5681s. Published online September 1, 1990.

Updated Version

Access the most recent version of this article at:
http://cancerres.aacrjournals.org/content/50/17_Supplement/5679s

E-mail alerts

[Sign up to receive free email-alerts](#) related to this article or journal.

Reprints and Subscriptions

To order reprints of this article or to subscribe to the journal, contact the AACR Publications Department at pubs@aacr.org.

Permissions

To request permission to re-use all or part of this article, contact the AACR Publications Department at permissions@aacr.org.